

Immediate Prosthetic Rehabilitation of Marginal Mandibulectomy Post Radiation Case by Single-Piece Implant - A Case Report

Vivek Gaur, Anita Gala Doshi¹, Subhangini Gandhi²

Department of Oromaxillofacial Surgery, Jaipur Dental College, Jaipur, Rajasthan, ¹Dentahealth Clinic, Mumbai, ²Ivory Clinic, Delhi, India

Abstract

Prosthetic rehabilitation post resection and radiotherapy demand a thorough understanding of the biomechanics of the jaw, its associated structures, and their post radiation changes at the bone level. Restoring lost structures can often pose a challenge, especially with regard to the dentition. Due to inadequate hard- and soft-tissue structures as well as their demand for “biologic osseointegration,” it is difficult to conduct immediate loading as a treatment option on conventional implants. Alternatives are today available. Since piece smooth surface cortical implants transmit occlusal forces at cortical bone/buttruss by engaging them, with or without reliance on the alveolar bone, it can be considered as an option. Here, we report a case of immediate loading with single-piece smooth surface implants in a male patient who had undergone a marginal mandibulectomy 3 years back for the removal of an oral squamous cell carcinoma of the retromolar trigone area that was closed by an anastomosed radial forearm flap, followed by radiation therapy. The dentition was restored successfully using a single piece smooth surface cortically anchored implant and reported favorable success and survival rate with high patient acceptance. Single piece corticobasal implant technology is one of the most predictable methods for the functional and sociopsychological correction, with minimal invasive immediate functional loading protocol restoring function and post resection surgical deformation of the jaw, thus improving lifestyle and survival.

Keywords: Immediate loading, marginal mandibulectomy, post radiation, single piece implant, twin occlusion

INTRODUCTION

The primary growth of malignant lesion is treated ideally by a local wide excision involving 2 cm margins of the normal soft and hard tissues as the tumor can extend beyond the radiological margins through the cancellous bone. Cortical bone offers resistance to the spread of the tumor, and hence, early cases can be treated adequately by wedge mandibulectomy,^[1] thereby avoiding morbidity in the patients but followed by therapeutic or elective neck dissection as required by the TNM staging system.^[2] The ablative surgery is followed by the chemotherapy and/or radiotherapy for the individual case. The retromolar trigone comprises one of the common sites for the oral squamous cell carcinoma (OSCC). After extirpation, the defect requires meticulous closure of the soft tissues as a part of the rehabilitation process. Treatment modalities for the reconstruction are implants such as reconstruction plates of stainless steel or titanium, custom made using CAD/CAM technology, vascularized grafts, or free bone graft. For the

soft-tissue reconstruction, we also have a number of options: local tissue advancement such as myomucosal tongue flaps, nasolabial flaps, temporalis muscle fascia flaps, and forehead flaps;^[3] distant flaps such as deltopectoral flap, pectoralis major flap myocutaneous and myocutaneous osseous composite flap, latissimus dorsi myocutaneous flap, sternomastoid myocutaneous flap, and platysma flap;^[3] free tissue transfer such as radial forearm flap and rectus abdominis flap.^[3]

Radial forearm flap is one of the most common free flaps, being ideal for the oral environment with minimal donor morbidity. It was mobilized in the case presented but was followed by the

Address for correspondence: Dr. Vivek Gaur,
417, K M Trade Tower, Adjacent Radisson Blu Hotel,
Kaushambi, Ghaziabad, Uttar Pradesh, India.
E-mail: drvivekgaur@yahoo.co.in

Received: 05-06-2020

Revised: 07-09-2020

Accepted: 14-09-2020

Published: 23-12-2020

This is an open access journal, and articles are distributed under the terms of the Creative Commons Attribution-NonCommercial-ShareAlike 4.0 License, which allows others to remix, tweak, and build upon the work non-commercially, as long as appropriate credit is given and the new creations are licensed under the identical terms.

For reprints contact: WKHLRPMedknow_reprints@wolterskluwer.com

How to cite this article: Gaur V, Doshi AG, Gandhi S. Immediate prosthetic rehabilitation of marginal mandibulectomy post radiation case by single-piece implant - A case report. *Ann Maxillofac Surg* 2020;10:501-6.

Access this article online

Quick Response Code:



Website:
www.amsjournal.com

DOI:
10.4103/ams.ams_260_20

abolishing of the vestibular sulcus, restricted mouth opening, scarring of the tissue of the affected area which was aggravated post radiation therapy, and movement of the mandible toward the extirpated side.^[4] Prosthetic rehabilitation of resected cases after radiotherapy demands a thorough understanding of the biomechanics of the jaw, its associated structures with post radiation changes at bone level. Single piece corticobasal implant technology is one of the most predictable methods for the functional and sociopsychological correction, with minimal invasive immediate functional loading protocol restoring function and post resection surgical deformation of the jaw, thus improving lifestyle and survival. The highlight of the case reported is the prosthetic rehabilitation of a complex situation displaying variation in the centric occlusal position in post radiation marginal mandibulectomy case. The immediate loading procedure was performed within 48 h with a flapless technique, following the protocols and concept of the corticobasal implantology. Moreover, it involved a full function by arranging the twin occlusion of nonanatomical teeth in the maxillary arch and in alignment with the linear occlusion.

CASE REPORT

This case report has been drafted according to the CARE guidelines. A 68-year-old male patient with a negative family history of cancer had undergone marginal mandibulectomy 3 years back for the extirpation of the right retromolar trigone region associated OSCC; consultation was made for the prosthetic rehabilitation of the defect as a result of post resection surgery [Figure 1]. Following surgery, the patient underwent “Shielded Radiation Therapy.”^[5] On clinical and radiological examination, it revealed that the defect was Class 1 Cantor and Curtis,^[6] which had been surgically closed by anastomosed radial forearm flap. Clinically, intraoral examination revealed the absence of the right side vestibular sulcus in the upper jaw and vestibular and lingual sulcus depth deficiency in the lower jaw with tongue deviation and hypertrophy toward the side of the defect [Figure 2]. Teeth present were upper right second premolar until the left 3rd molar in the maxilla. And from the lower right lateral incisor till left 3rd molar with a functional fixed prosthesis. Extraoral examination revealed a midline surgical scar with restricted mouth opening, with the mandible deviating toward the right side. Scarring at the right lip commissure was noticed.

The patient was informed of the various treatment modalities such as removable cast partial denture, removal implant-supported prosthesis, fixed implant-supported prosthesis, and delayed and immediate loading. For the implants retained prosthesis, two options were proposed, delayed loading by two-stage conventional design and immediate loading by single piece smooth surface basal/cortically anchored implant. The patient requested to undergo implant borne immediate loading fixed restoration. Routine preoperative hematological examination was performed, and the consent form was signed by the patient. After the informed consent was obtained, the patient was operated under local infiltration in a routine dental operatory. The left upper

and lower third molars were extracted along with the decayed and mobile upper right premolars and the lower left canine as well as all lower incisors under Lignox® 2% A (lignocaine with adrenaline 1:80,000) infiltration. A single-piece, smooth-surfaced cortically anchored implant (BECES® Type) (Simpladent GmbH, Switzerland) was placed following the guidelines of the technology of the cortically anchored implant^[7-9] [Figure 3]. The surgery was itself challenging because of the limited access in the mouth due to restricted mouth opening and deficient vestibular and lingual sulcus with angular cheilosis at the resected side. Implants were placed in the maxilla by engaging the pterygoid apophysis, right alveolar-palatine bone, and the nasal floor [Figure 4]. All implants had 3.6 mm thread diameter, and they were placed in a flapless procedure. In the lower jaw, all 3.6 mm diameter BECES® implants were likewise placed flapless in a length of 17 mm, 26 mm, 23 mm, and 20 mm from distal to anterior of the lower jaw right side, respectively.^[10,11] Implant placement was planned to achieve maximum anteroposterior spread avoiding cantilever; abutment emergence was planned to achieve minimal interference from the tongue and buccal mucosa as of absence of the right vestibular sulcus and lingual sulcus deficiency. The lingual cortex was engaged by the most distal implant, whereas the 2nd but the last implant anchored in the base of the mandible, being transverse mandibular buttress^[12] and between the intermental foramen [Figure 5]. The biggest technical problems were caused by the necessary implant length: single piece implants with a length of 17 mm to 26 mm had to be inserted with minimal mouth opening. Postoperatively, analgesic Meftal-Forte® (combination of mefenamic acid 500 mg and paracetamol 325 mg) twice daily for 3 days was prescribed with Oraways® gel (triamcinolone acetonide 0.1% w/w) to be applied locally on the tongue ulcers and right angular cheilosis, followed by Betadine® 2% (povidone-iodine) mouth wash oral rinse thrice daily. Impression caps were placed on the single piece implants immediately after implant placement, and the impression was made with polyvinyl siloxane (Flexceed® GC) with customized trays (having minimal flanges on the right side both upper and lower), which was important because of restricted right buccal space, angular cheilosis, and obstruction from the tongue. The mandible was guided gently for maximum intercuspation of existing teeth and the jaw relationship was recorded with aluminum reinforced Alu-Wax®. Mandibular teeth were arranged in the neutral zone and are muscularly balanced. So that the chewing surfaces do not come in contact with buccal and lingual mucosa the resected site was devoid of vestibular and lingual sulcus due to high attachment of radial foramen free flap mobilized for the closure of post resection defect. Fixed prosthesis was delivered the next day of implant placement having lower metal to ceramic and upper metal to acrylic (PMMA) with highly polished convex intaglio surface [Figure 6]. Special modification for this particular case was made by fabricating maxillary twin occlusion masticatory surfaces [Figure 7]. The final prosthesis was cemented by resin-modified Fuji Plus® (GC Company, Japan) and linear occlusion was provided [Figures 8-10]. The fabricated prosthesis was sanitary/self-cleansing in the posterior region with an anterior modified ridge lap.

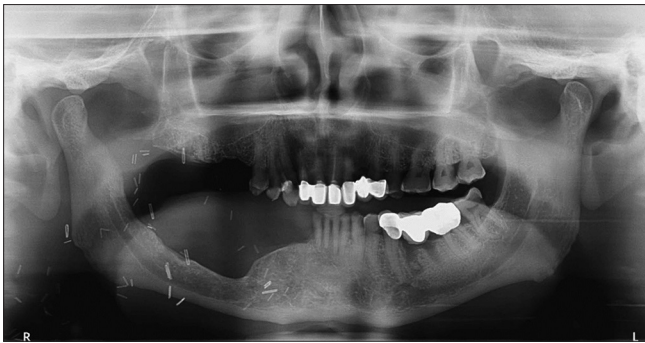


Figure 1: Preoperative panoramic picture

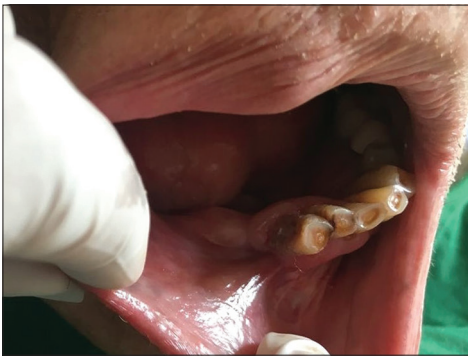

Figure 2: Intra-oral view of the patient preoperatively

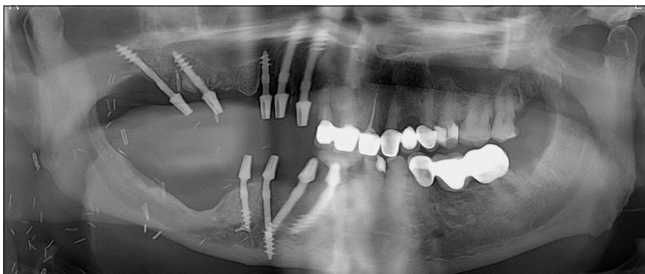


Figure 3: Postoperative panoramic picture

The patient started chewing the food the very next day, but the speech took a week's time to get back to normal. Follow-ups were scheduled and done 2 days and a week after cementing, the final prosthesis, 3 months, 6 months, and at 1 year; follow-up panorama [Figure 11] was also made. Recently, a 3-year follow-up panorama [Figure 12] and cone-beam computed tomography scan [Figure 13] were obtained, and findings revealed good success without any bone loss around implants. The rules for the design of the occlusal contacts and masticatory surfaces have been described in Ihde and Ihde.^[9] The patient's chewing pattern instantly changed after the insertion of the restorations from a strictly anterior pattern to a bilateral pattern. Infact, the patient's mandibular movement was toward the resected side by suprahyoid muscles pull and uncompensated contralateral internal pterygoid muscle action, which was stabilized by the twin occlusion teeth arrangement done in maxillary prosthesis to achieve the centric relation of the patient at rest and restoring the vertical.

DISCUSSION

The anatomic and physiologic discussion of Boucher,^[13] Pendleton,^[14] Silverman,^[15] and MacMillin^[16] laid the foundation of modern prosthetic treatment. The patient mandibular movements, swallowing, articulation, respiration, control of saliva, and mastication are adversely affected by the ablative surgeries of the mandible. The procedure of marginal mandibulectomy involves extirpation of the involved portion of the alveolar and body of the mandible saving the lower border of the mandible, the mucoperiosteum of the jaw, the lingual and buccal sulcus mucosa, a portion of the base of the tongue with mylohyoid muscle as it is the floor of the mouth, the lingual and inferior alveolar nerves if involved, the sublingual and submandibular salivary glands, and sometimes, the anterior part of the digastric muscle. This results in the scar tissue in the region of the resection. The involvement of the tongue and the mylohyoid muscle causes a reduction in tongue mobility and interferes in raising the floor of the mouth as needed in deglutition. When the radiation therapy is followed by the ablative surgery of the pathology, the patient suffers from partial xerostomia and thick salivary secretions that complicate the acceptance of the prosthesis. Radiation therapy can lead to both early and late-onset tissue reactions.^[17,18] The late reactions are typical radiation-induced fibrosis and bone demineralization, in conjunction with a diminished ability to resist infection. The irradiated osseous structure is more liable to infection because of diminished perfusion. Moreover, radiation causes endarteritis,^[19] resulting in tissue hypoxia, hypocellularity, and hypovascularity resulting in osteoradionecrosis. The vascularized flaps such as free forearm flap are preferred over nonvascularized flap to avoid complications post radiotherapy.^[20] Forearm flaps have been widely accepted for intra-oral reconstruction.^[21] It can be applied to any part of the oral cavity because of its flexibility, thinness, and good vascularity. In addition, it provides esthetically satisfactory postoperative recovery in terms of both color and firmness.

Smooth surface single piece BECES[®] which are cortically anchored dental implants are a preferred choice in post radiotherapy cases as there is a need to reconstruct the functional prosthesis which is least attracted to plaque and without any microgap junction leading to incidences of peri-implantitis.^[22-30] The single piece smooth surface basal/cortically anchored implants are advantageous for such a case because they do not require active biologic osseointegration (which bone after radiation hardly delivers) nor "healing time," and at the same time, the risk of descending infections along the polished vertical shaft of the implant is low.^[31,32] The basal/cortically anchored implant-supported prosthesis has a positive impact on oral health and highly increased patient satisfaction.^[33]

The prosthetic restoration of resected mandibular cases demands higher understanding of mandibular post resected

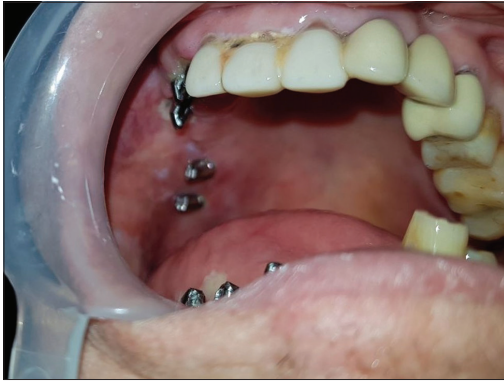

Figure 4: Implants placed without raising the flap in the maxilla

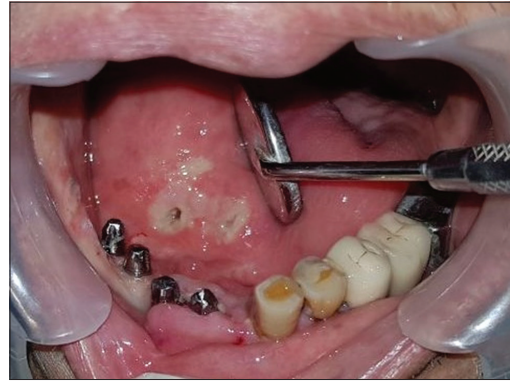


Figure 5: Implants placed without raising the flap in the mandible

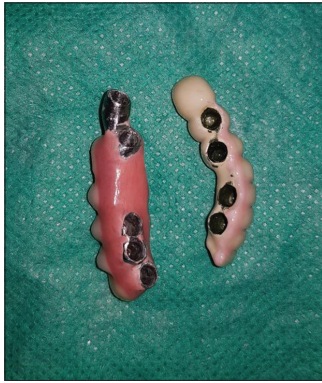

Figure 6: Highly polished convex tissue surface of the prosthesis

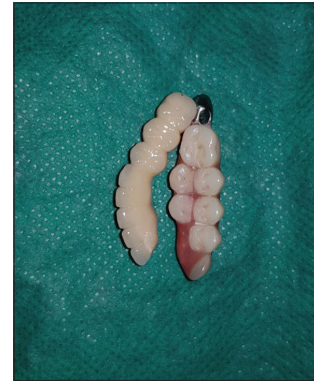

Figure 7: Occlusal aspect of the prosthesis

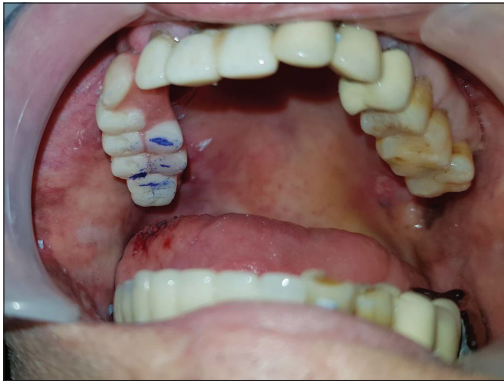

Figure 8: Maxillary double row teeth metal to acrylic prosthesis

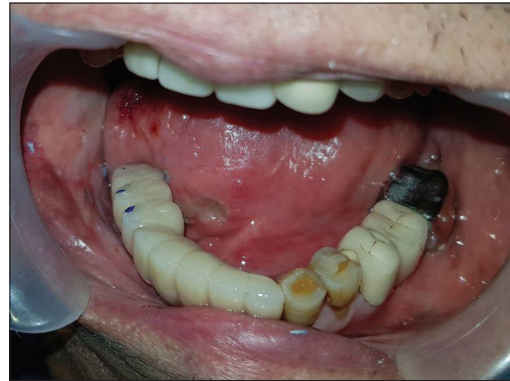

Figure 9: Lower ceramic prosthesis

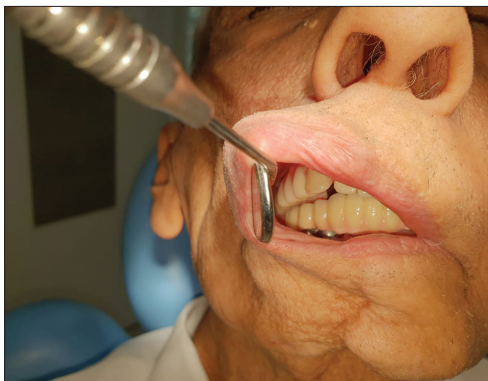

Figure 10: One point contact linear occlusion

functional movement. When a part of the mandible is resected, the movements of the mandible in the functional range and occlusal proprioception differ from that of movements and occlusion of the normal mandible as the residual segment will retrude and deviate toward the surgical site. During mastication, the entire envelope of motion occurs on the surgical defect side. The frontal plane rotation occurs due to the loss of proprioceptive sense of occlusion, which leads to the uncoordinated and less precise movement of the mandible. Furthermore, due to attachment loss of muscles of mastication on the surgical side, there is a significant rotation of the mandible upon forceful closure. When the force of closure increases, the residual

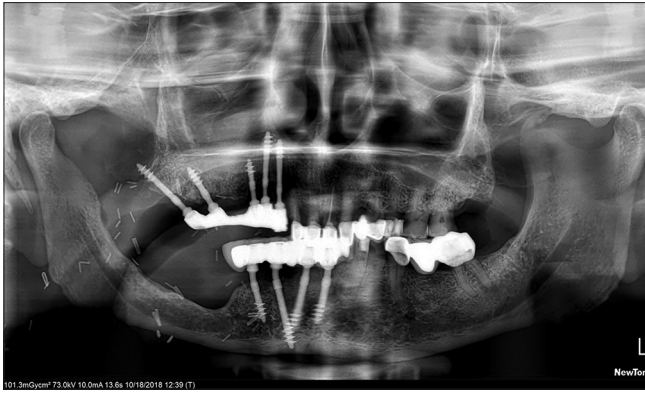


Figure 11: One-year follow-up panoramic picture

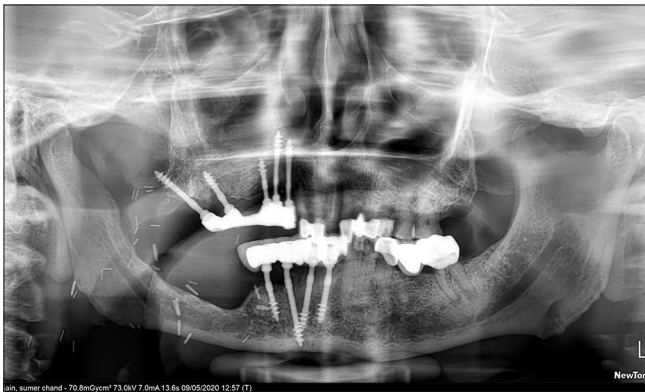


Figure 12: Three-year follow-up panoramic picture

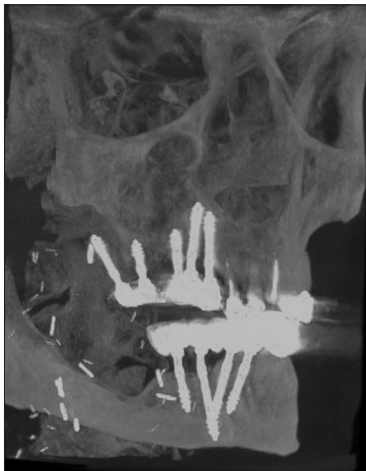

Figure 13: Three-year follow-up three-dimensional construction picture

mandible actually rotates through the frontal plane.^[34] The medial pterygoid muscle and mylohyoid muscles; a part of masticatory muscles; always pull the mandible toward the resected side, thus misbalancing the equilibrium of masseter and medial pterygoid muscles. The muscles of mastication are normally in a state of equilibrium when the opposing teeth are lightly touching. The centric occlusal position of the mandibulectomy patient is medially placed with a corresponding loss of vertical dimension. Masticatory

forces can be exerted along this deflected pathway, but the patient is seldom capable of sufficiently coordinated muscular strength for normal mastication.^[35] In many cases, the patient can approximate the presurgical occlusal centric, but the restoration of the original occlusal vertical dimension may interfere with compensatory speech and deglutition, resulting in diminished masticatory function. By arranging the twin occlusion of nonanatomical teeth and keeping a linear occlusion,^[36-38] the twin occlusion teeth arrangement act like a guiding plane where the palatal row of teeth is in intercuspation and vestibular row supports the vestibular mucosa and complete esthetic demand. This twin occlusion guiding plane prosthesis in fact helps program the resected side muscles and improve coordination. Care is taken to make lateral/eccentric movements of the lower jaw free from interferences. The presented occlusal scheme helps the patient to achieve mastication as of varied centric occlusal position post resection surgery. The case presented provided maxillary hybrid metal to acrylic (PMMA) prosthesis with twin occlusion of nonanatomical teeth and lower prosthesis metal to ceramic having linear contact on the maxillary prosthesis from mesial to distal ridges. The patient achieved smooth masticatory function from the balance on both sides. This situation remained stable and was found in all follow-up examinations. The patient felt very satisfied with the treatment owing to the immediate loading procedure that was conducted within 48 h after implant placement. As the procedure was flapless, postoperative pain was neglectable. Due to the minimal surgical trauma, the time required to return back to normal function and chewing was significantly reduced. Our case had a follow-up of 3 years, and we reported the success of the implant along with the absence of bone loss, mobility, inflammation, and pain.

CONCLUSION

The prosthetic rehabilitation of a complex case displaying varied centric occlusal position on a post radiation therapy marginal resected case with full function and acceptance from the patient was achieved with success. The case was completed within 24 h with minimal surgical trauma being flapless procedure, following the protocols and concept of the cortically anchored implants. This type of treatment can be very advantageous owing to the fact that this procedure could be performed without the use of bone grafts. Moreover, this procedure involves minimal surgical trauma and involved immediate loading which help reduce the overall chairside time and number of patient appointments. Furthermore, smooth surface, single-piece cortical implants have a certain advantage over regular surface treated two-piece implants as there are no delayed complications such as abutment screw loosening/fracture or peri-implantitis to be expected.

Declaration of patient consent

The authors certify that they have obtained all appropriate patient consent forms. In the form the patient(s) has/have

given his/her/their consent for his/her/their images and other clinical information to be reported in the journal. The patients understand that their names and initials will not be published and due efforts will be made to conceal their identity, but anonymity cannot be guaranteed.

Financial support and sponsorship

Nil.

Conflicts of interest

There are no conflicts of interest.

REFERENCES

- Awadalkreem F, Khalifa N, Ahmad AG, Suliman AM, Osman M. Rehabilitation of an irradiated marginal mandibulectomy patient using immediately loaded basal implant-supported fixed prostheses and hyperbaric oxygen therapy: A 2-year follow-up. *Int J Surg Case Rep* 2020;71:297-302.
- Zanoni DK, Patel SG, Shah JP. Changes in the 8th Edition of the American Joint Committee on Cancer (AJCC) Staging of Head and Neck Cancer: Rationale and Implications. *Curr Oncol Rep* 2019;21:52.
- Borle RM. *Textbook of Oral and Maxillofacial Surgery*. 1st ed. Jaypee brothers, Mumbai, India; 2014.
- Mahajan T, Trivedi R, Singh S, Sangur R. Prosthetic management of edentulous mandibulectomy patient with modified occlusion - A case report. *Rama Univ J Dent Sci* 2015;2:42-5.
- Zhang S, Jiang S, Zhang Q, Lin S, Wang R, Zhou X, et al. Reduction in stray radiation dose using a body-shielding device during external radiation therapy. *J Appl Clin Med Phys* 2017;18:206-13.
- Cantor R, Curtis TA. Prosthetic management of edentulous mandibulectomy patients. I. Anatomic, physiologic, and psychologic considerations. *J Prosthet Dent* 1971;25:446-57.
- Oleg D, Alexander L, Vitomir KS. Immediate-functional loading concept with one-piece implants [BECES/BECES N/KOS/BOI] in the mandible and maxilla- a multi-centre retrospective clinical study. *J Evol Med Dent Sci* 2019;8:306-15.
- Ihde S, Kopp S, Maier T. Comparison of implant survival with implants placed in acceptable and compromised bone: A literature review. *J Maxillofac Oral Surg* 2009;8:1-7.
- Ihde S, Ihde A. *Cookbook Mastication*. 4th ed. International Implant Foundation Publishing; 2020.
- International Implant Foundation: Konsensus on 16 Methods for the placement of Basal Implants. Available from: <http://implantfoundation.org/en/consensus-16-approved-methods-2018-menu-en>. [Last Accessed on 2016 Apr 15].
- Ihde S, Ihde A, Lysenko V, Konstantinović V, Pálka L, et al. *New Systematic Terminology of Cortical Bone Areas for Osseo-Fixed Implants in Strategic Oral Implantology*. Vol. 1. Germany: J J Anatomy; 2016. p. 007.
- Winegar BA, Murillo H, Tantiwongkosi B. Spectrum of critical imaging findings in complex facial skeletal trauma. *Radiographics* 2013;33:3-19.
- Boucher C. Impressions of complete dentures. *J Am Dent Assoc* 1944;1:472-91.
- Pendleton EC. Anatomy of the face and mouth from the standpoint of the denture prosthodontist. *J Am Dent Assoc* 1946;33:219-34.
- Silverman SI. Denture prosthesis and functional anatomy of the maxillofacial structures. *J Prosth Dent* 1956;1:472-491.
- MacMillin HW. Anatomy of the throat, mylohyoid region and mandible in relation to mandibular artificial dentures. *J Am Dent Assoc* 1937;23:446-457.
- Pogrel MA, Podlesh S, Anthony JP, Alexander J. A comparison of vascularized and nonvascularized bone grafts for reconstruction of mandibular continuity defects. *J Oral Maxillofac Surg* 1997;55:1200-6.
- Granström G, Jacobsson M, Tjellström A. Titanium implants in irradiated tissue: Benefits from hyperbaric oxygen. *Int J Oral Maxillofac Implants* 1992;7:15-25.
- Marx RE. A new concept in the treatment of osteoradionecrosis. *J Oral Maxillofac Surg* 1983;41:351-7.
- Hirsch DL, Bell RB, Dierks EJ, Potter JK, Potter BE. Analysis of microvascular free flaps for reconstruction of advanced mandibular osteoradionecrosis: A retrospective cohort study. *J Oral Maxillofac Surg* 2008;66:2545-56.
- Shibahara T, Noma H, Takeda E, Hashimoto S. Morphologic changes in forearm flaps of the oral cavity. *J Oral Maxillofac Surg* 2000;58:495-9.
- Jacobs R, Pittayapat P, van Steenberghe D, De Mars G, Gijbels F, Van Der Donck A, et al. A split-mouth comparative study up to 16 years of two screw-shaped titanium implant systems. *J Clin Periodontol* 2010;37:1119-27.
- Mouhyi J, Dohan Ehrenfest DM, Albrektsson T. The peri-implantitis: Implant surfaces, microstructure, and physicochemical aspects. *Clin Implant Dent Relat Res* 2012;14:170-83.
- Quirynen M, van der Mei HC, Bollen CM, Schotte A, Marechal M, Doornbusch GI, et al. An *in vivo* study of the influence of the surface roughness of implants on the microbiology of supra- and subgingival plaque. *J Dent Res* 1993;72:1304-9.
- Subramani K, Jung RE, Molenberg A, Hammerle CH. Biofilm on dental implants: A review of the literature. *Int J Oral Maxillofac Implants* 2009;24:616-26.
- Teughels W, Van Assche N, Sliepen I, Quirynen M. Effect of material characteristics and/or surface topography on biofilm development. *Clin Oral Implants Res* 2006;17 Suppl 2:68-81.
- Esposito M, Ardebili Y, Worthington HV. Interventions for replacing missing teeth: Different types of dental implants. *Cochrane Database Syst Rev* 2014;22:CD003815.
- Esposito M, Pistilli R, Barausse C, Felice P. Three-year results from a randomised controlled trial comparing prostheses supported by 5-mm long implants or by longer implants in augmented bone in posterior atrophic edentulous jaws. *Eur J Oral Implantol* 2014;7:383-95.
- Marrone A, Lasserre J, Bercy P, Brex MC. Prevalence and risk factors for peri-implant disease in Belgian adults. *Clin Oral Implants Res* 2013;24:934-40.
- Sequeira VT, Abhyankar V, Fernandes G. Prevention of peri-implantitis: A narrative review. *J Dent Oral Care Med* 2018;4:106.
- Ihde S. Indications and treatment modalities with corticobasal jaw implants. *Ann Maxillofac Surg* 2019;9:379-86.
- Ihde S. *Principles of BOI*. Springer-Verlag Berlin Heidelberg, 2005.
- Awadalkreem F, Khalifa N, Satti A, Suleiman AM. The influence of immediately loaded basal implant treatment on patient satisfaction. *Int J Dent* 2020;2020:6590202.
- Koralakunte PR, Shammur SN, Iynalli RV, Shivmurthy S. Prosthetic management of hemimandibulectomy patient with guiding plane and twin occlusion prosthesis. *J Nat Sci Biol Med* 2015;6:449-53.
- Ballard JL, Kerner E, Tyson J, Ashford J, Rees R. Adenocarcinoma of the tongue complicated by a hemimandibulectomy: Soft tissue support for a tongue prosthesis in an edentulous glossectomy patient. *J Prosthet Dent* 1986;56:470-3.
- Rangarajan V, Yogesh PB, Gajapathi B, Ibrahim MM, Kumar RG, Karthik M. Concepts of occlusion in prosthodontics: A literature review, part II. *J Indian Prosthodont Soc* 2016;16:8-14.
- Rangarajan V, Gajapathi B, Yogesh PB, Ibrahim MM, Kumar RG, Karthik P. Concepts of occlusion in prosthodontics: A literature review, part I. *J Indian Prosthodont Soc* 2015;15:200-5.
- Carlsson GE. Dental occlusion: Modern concepts and their application in implant prosthodontics. *Odontology* 2009;97:8-17.