



ISSN: 0975-833X

Available online at <http://www.journalcra.com>

International Journal of Current Research  
Vol. 11, Issue, 10, pp.7532-7535, October, 2019

DOI: <https://doi.org/10.24941/ijcr.36431.10.2019>

INTERNATIONAL JOURNAL  
OF CURRENT RESEARCH

## CASE REPORT

# FULL MOUTH REHABILITATION USING IMMEDIATE LOADING BASAL IMPLANTS IN A SYSTEMIC LUPUS ERYTHEMATOSUS PATIENT: A CASE REPORT

<sup>1,\*</sup>Vivek Gaur, <sup>2</sup>Feminath and <sup>3</sup>Anita Gala Doshi

<sup>1</sup>Oral Surgeon, Ranpur, Kota, Rajasthan, India

<sup>2</sup>Private dental practice, Vattiyoorkavu, Trivandrum, Kerala, India

<sup>3</sup>Prosthodontist, Private Dental Practice, Mumbai, Maharashtra, India

### ARTICLE INFO

#### Article History:

Received 04<sup>th</sup> July, 2019

Received in revised form

19<sup>th</sup> August, 2019

Accepted 15<sup>th</sup> September, 2019

Published online 30<sup>th</sup> October, 2019

#### Key Words:

BCS®(Basal Cortical Screw) implants,  
Hybrid denture, Systemic Lupus  
Erythematosus.

\*Corresponding author: Vivek Gaur

Copyright©2019, Vivek Gaur et al. This is an open access article distributed under the Creative Commons Attribution License, which permits unrestricted use, distribution, and reproduction in any medium, provided the original work is properly cited.

Citation: Vivek Gaur, Feminath and Anita Gala Doshi, 2019. "Full mouth rehabilitation using immediate loading basal implants in a systemic lupus erythematosus patient: A case report", *International Journal of Current Research*, 11, (10), 7532-7535.

### ABSTRACT

Systemic lupus erythematosus (SLE) presents as a chronic inflammatory autoimmune disease that can often demonstrate multisystem involvement. Since, immune-suppressive drugs are used in the treatment of this disease, it can possess an elevated risk of infection and delay healing. Moreover, damage to the salivary glands in this disease leads to reduced salivation. Together, these complications can be a primary concern in dental treatment procedures owing to inability to maintain oral hygiene and risk of implant failure. This is the first case report in literature to our knowledge and it represents a treatment option and procedure for immediate full mouth rehabilitation after extraction without raising flaps using basal cortical screw implant in a patient who was on corticosteroid for over 20 years as she was diagnosed with Systemic Lupus Erythematosus. Since there are very few cases of SLE reported in literature with the use of oral implants, treating these patients can often pose a challenge.

## INTRODUCTION

Systemic lupus erythematosus (SLE) is a chronic, autoimmune, inflammatory disease with multiple organ involvement and a broad spectrum of clinical manifestations, including mucocutaneous, cardiac, renal, pulmonary, and musculoskeletal complications (Wang *et al.*, 2019; Bardare *et al.*, 1990; Gurevitz *et al.*, 2013). Moreover, it is associated with connective tissue and blood vessel disorder followed by recurrent episodes of acute or chronic inflammation and alternating periods of remission and flares (Gurevitz *et al.*, 2013). SLE affects women 10 times more than men and manifests as oral lesions (red macula or plaque to ulcerations, which may be surrounded by white irradiating striae, and white plaque on a pigmented mucosa involving the hard palate, lips, and buccal mucosa) in 10% cases (Gurevitz *et al.*, 2013). Women are affected about 10 times more frequently than men (Gurevitz *et al.*, 2013). More than 40% of patients with SLE experience oral lesions. Often, these patients reports with symptoms and clinical lesions of caries, gingivitis, or even periodontitis due to poor oral hygiene (Correa *et al.*, 2018; Jensen *et al.*, 1999). Patients with SLE may also have secondary Sjögren syndrome, which may manifest with a dry mouth. Insufficient saliva and limited mouth opening can complicate the use of a prostheses (Correa *et al.*, 2018). The original basal implants were designed by Lobello using two

separate components. Subsequently Julliet in 1975 developed a single piece basal implant which was granted a US patent. It was Dr. Gerard Scortecchi (from 1985) and Prof. Stefan Ihde (from 1998) who turned their concept of basal implants into successful and marketable product (Ihde *et al.*, 2009; Goldmann *et al.*, 2008; Ihde *et al.*, 2008). Initially the basal implants were inserted into the jawbone in a lateral path and anchored into the buccal and palatal or lingual cortical bone. Science has evolved in such a way that new basal implants are inserted through crestal approach and screws are anchored in the basal bone. The predictability of these implants are due to the fact that these implants are anchored in the resorption free basal cortical bone and not alveolar bone (Goldmann *et al.*, 2008; Ihde *et al.*, 2008; Ihde, 2018). The purpose of the present report is to describe the oral rehabilitation of a patient with SLE using basal dental implants in a fixed Appliance. The special consideration of the patient's medical complications are outlined.

## CASE REPORT

A 62 year old female suffering from SLE for the past 20 years and who was under Prednisolone 4mg daily and Cholecalciferol 200 units twice daily reported to our dental office with partial edentulous arches. Intra oral examination revealed partially edentulous upper and lower arch with

generalized periodontal pocket formation and grade III mobility (see Fig. 1). Extra orally no relevant findings were noted. The panoramic radiograph taken shows generalized bone loss and maxillary sinus floor was pneumatized almost till the crest of alveolar bone. From intra oral and OPG examination prognosis of the remaining teeth was ascertained to be poor. Hence total extraction followed by strategic immediate loading implants was planned. After obtaining Medical clearance the treatment was scheduled to be completed in three days. After informing the patient about the treatment plan, informed consent was obtained. Following which, on day one, the remaining teeth were extracted under local anesthesia. All the implants were placed without raising flaps. In the maxilla two strategic pterygoid implants were placed distal to the maxillary sinus on each arch. In the anterior region one implant was placed on each side on the lateral wall of the nose and two each on the floor of the nose (see Fig. 2). In the mandible posterior to the mental foramen two implants were placed on the each side engaging the lingual cortical bone. Anterior to the mental foramen two implants were placed directed towards symphysis mental region. Extraction site were approximated by suturing with 3-0 braided silk. Impression caps were placed on the implants and impression of the maxillary and mandibular arches were made using heavy body condensation silicone elastomer. Impression was sent to the lab for the fabrication of the metal framework.

and 5). Occlusion was confined to a supporting polygon with the occluding surfaces on the mesial side of the first molar and first and second premolars. The patient was satisfied by the esthetics and restored masticatory function (see Fig. 6 and 7). After one year metal acrylic restoration was changed to permanent metal ceramic restoration. All implants were firm. Preliminary three years recall showed good healing.

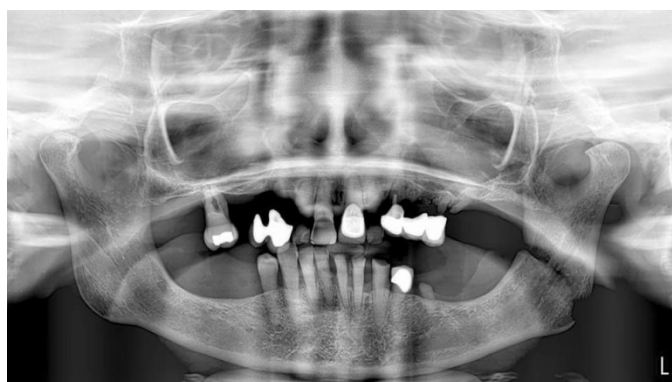

Figure 1. Pre-operative radiograph

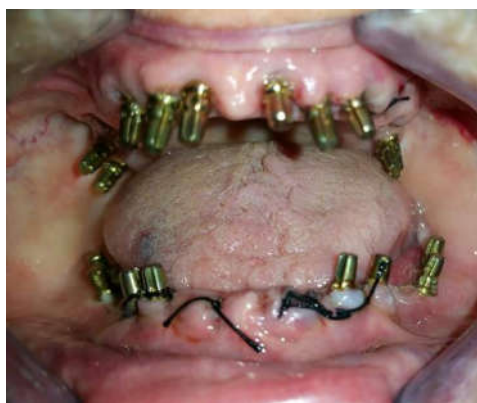

Figure 2. Implant placement

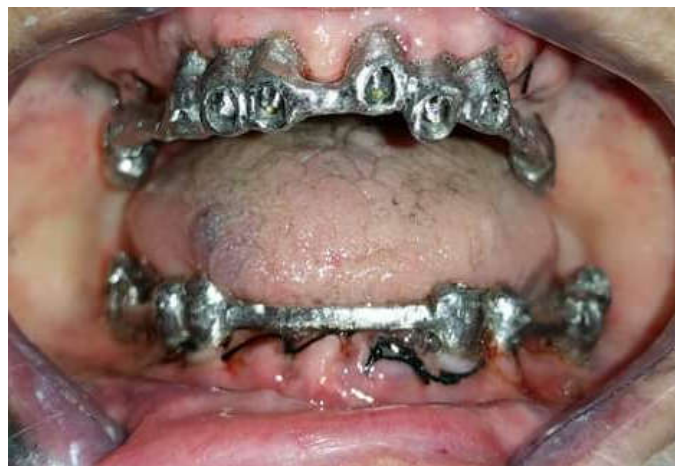

Figure 3. Metal framework trial

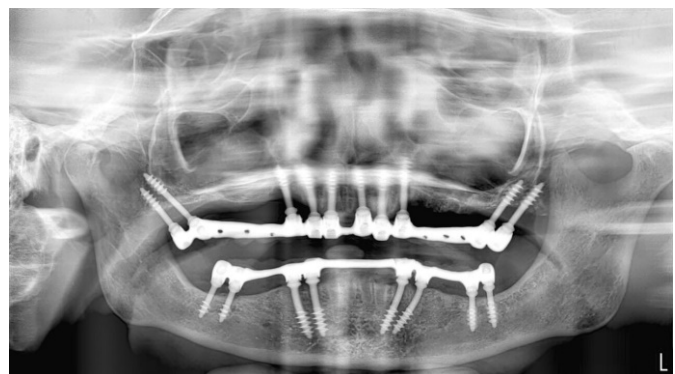


Figure 4. Post-operative radiograph

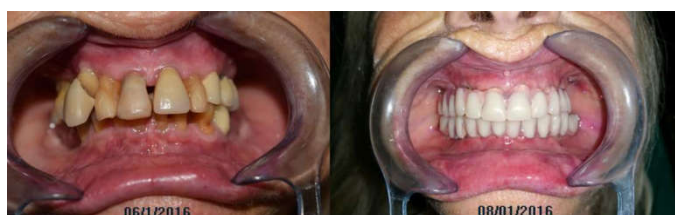

Figure 5. Pre and Post-operative intra oral

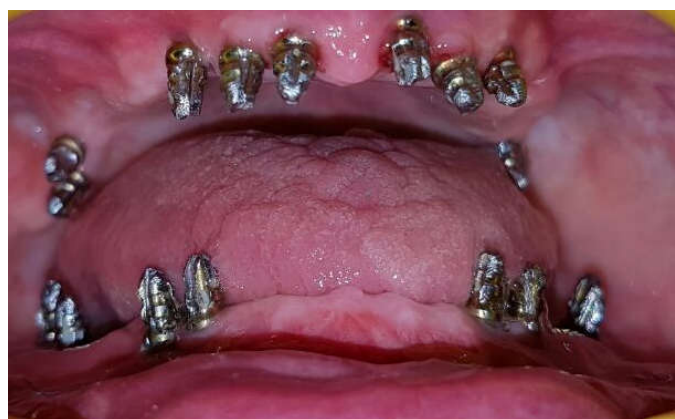
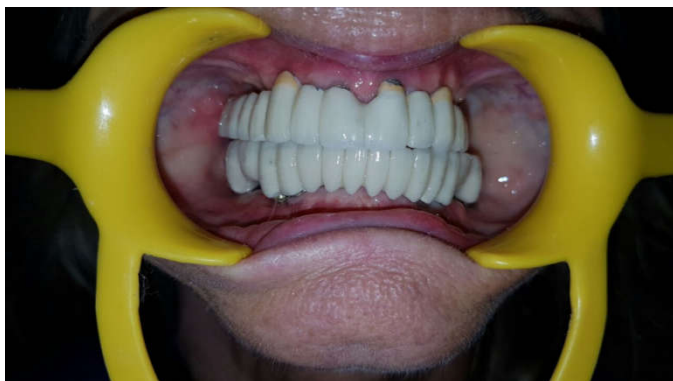
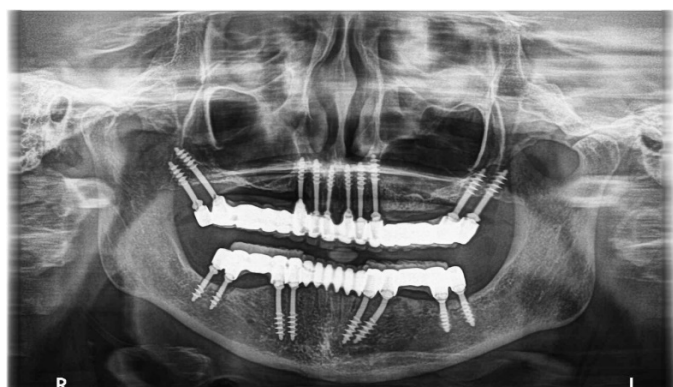Figure 6. After one year, all the prostheses were removed and implants were firm

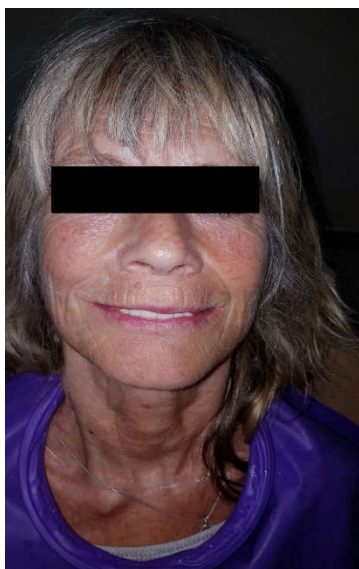On the second day, the fit of the metal framework was verified on the patient (see Fig. 3). The metal framework was sent to the lab for the fabrication of the metal to acrylic hybrid prosthesis. Consequently, on the third day, the surgical site was irrigated with Betadine solution. Sutures were removed. The hybrid prosthesis was cemented over the implants after accessing the occlusion, retention and resistance (see Fig. 4



**Figure 7. Intra oral post-operative view with new porcelain fused to metal prosthesis that was fabricated**



**Figure 8. Post-operative radiograph (3 years)**



**Figure 9. Extra oral post-operative view**

## DISCUSSION

Implant treatment for patients suffering from SLE is not adequately documented in literature leading to often possible mistreatment of patients<sup>10</sup>. In this paper, the case of uneventful installation of basal dental implants and successful prosthetic rehabilitation of a patient with SLE was presented, and specific considerations with which a dentist should be familiar when treating such patients were pointed out. Pathogenesis of SLE includes deposition of autoimmune antibody complexes in the connective tissue of various organs with subsequent immune response. 90% of women are amongst the most affected in SLE. The presence of SLE may impair orofacial structures and

functions in various ways. Major complaints include xerostomia, burning and tingling of oral mucosa, and painful mucosal lesions. In the presented case, typical bilateral, painful mucosal lesions localized on buccal mucosa were confirmed, with symptoms of xerostomia and sore mouth, as well as the presence of unsatisfactory mobile dentures. Furthermore, decreased salivary flow can lead to periodontal disease in patients with SLE. Mutlu *et al.* (1993) reported that patients with SLE have significantly lower periodontal probing depths compared with healthy controls. They also stressed that systemic drugs used in SLE such as corticosteroids and nonsteroidal anti-inflammatory drugs may account for this situation. Because of the ongoing periodontal problems, the patient's old fixed partial dentures were removed, and provisional crowns were made during the periodontal treatment and healing process. Keller *et al.* (2004) has previously reported that long-term use of corticosteroids may result in osteoporosis that can eventually produce negative effects on osseointegrated dental implants. On the other hand, (Fujimoto *et al.*, 1996 & 1998) stressed that long-term use of corticosteroids does not affect osseointegrated dental implants, based on the fact that osteoporosis has only a minor negative effect on jaws compared to other bones. In our study, no remarkable bone loss around the implants was seen in the patient during the 36-month follow-up. Moreover, Patients on the steroid therapy are often osteoporotic. It is a daunting task to rehabilitate such patients using conventional implant therapy. Conventional implants will end up in decreased primary stability of the implants as the bone mineral density is significantly reduced in osteoporosis. In basal implant therapy the basal implants are anchored in basal cortical bone which is not prone to resorption. The basal cortical bone is resorption free as they are more mineralized due to muscle attachments. Basal implant therapy does not require any augmentation procedures like bone grafting and sinus lifting as basal implants derive anchorage from the basal cortical bone.

## Conclusion

The patient was rehabilitated with a fixed prosthesis supported by eighteen strategic/basal dental implants. No complication was observed during either the dental treatments or follow-ups. In view of this case report and a review of pertinent literature, we recommend that the dental practitioner consider basal dental implants as a preferred approach in the oral rehabilitation of patients with SLE (see fig. 8 and 9). This case report also presents a viable treatment option for patients with osteoporosis for prosthetic rehabilitation using basal implants.

**Sources of funding: Nil**

## REFERENCES

- Wang Y, Zhao R, Gu C, *et al.* 2019. The impact of systemic lupus erythematosus on health-related quality of life assessed using the SF-36: a systematic review and meta-analysis. *Psychology, health & medicine*, 1-14.
- Bardare M, De Vio M, Giani M, Cohen E. 1990. [Systemic lupus erythematosus in childhood: review of the literature and personal observations on 32 cases]. *La Pediatriamedica e chirurgica: Medical and surgical pediatrics*, 12(6):577-586.
- Gurevitz SL, Snyder JA, Wessel EK, Frey J, Williamson BA. 2013. Systemic lupus erythematosus: a review of the

- disease and treatment options. *The Consultant pharmacist : the Journal of the American Society of Consultant Pharmacists*, 28(2):110-121.
- Correa JD, Branco LGA, Calderaro DC, et al. 2018. Impact of systemic lupus erythematosus on oral health-related quality of life. *Lupus*, 27(2):283-289.
- Jensen JL, Bergem HO, Gilboe IM, Husby G, Axell T. 1999. Oral and ocular sicca symptoms and findings are prevalent in systemic lupus erythematosus. *Journal of oral pathology & medicine: official publication of the International Association of Oral Pathologists and the American Academy of Oral Pathology*, 28(7):317-322.
- Ihde S, Kopp S, Maier T. 2009. Comparison of implant survival with implants placed in acceptable and compromised bone: a literature review. *Journal of maxillofacial and oral surgery*, 8(1):1-7.
- Goldmann T, Ihde S, Kuzelka J, Himmlova L. 2008. Bendable vs. angulated dental implants: consideration of elastic and plastic material properties based on experimental implant material data and FEA. *Biomedical papers of the Medical Faculty of the University Palacky, Olomouc, Czechoslovakia*, 152(2):309-316.
- Ihde S, Goldmann T, Himmlova L, Aleksic Z. 2008. The use of finite element analysis to model bone-implant contact with basal implants. *Oral surgery, Oral Medicine, oral pathology, Oral Radiology, and Endodontics*, 106(1):39-48.
- Ihde S, Ihde A. 2018. Considerations Regarding Dental Implant Surfaces, Bone Reaction and "Peri-implantitis". *Annals of Maxillofacial Surgery*, 8(2):365-368.
- Ergun S, Katz J, Cifter ED, Koray M, Esen BA, Tanyeri H. 2010. Implant-supported oral rehabilitation of a patient with systemic lupus erythematosus: case report and review of the literature. *Quintessence International*, 41(10):863-867.
- Mutlu S, Richards A, Maddison P, Scully C. 1993. Gingival and periodontal health in systemic lupus erythematosus. *Community Dentistry and Oral Epidemiology*, 21(3):158-161.
- Keller JC, Stewart M, Roehm M, Schneider GB. 2004. Osteoporosis-like bone conditions affect osseointegration of implants. *The International Journal of Oral & Maxillofacial Implants*, 19(5):687-694.
- Fujimoto T, Niimi A, Sawai T, Ueda M. 1998. Effects of steroid-induced osteoporosis on osseointegration of titanium implants. *The International Journal of Oral & Maxillofacial Implants*, 13(2):183-189.
- Fujimoto T, Niimi A, Nakai H, Ueda M. 1996. Osseointegrated implants in a patient with osteoporosis: a case report. *The International Journal of Oral & Maxillofacial Implants*, 11(4):539-542.

\*\*\*\*\*