

# Dental Implant Treatment and Immediate Functional Loading (1). Case Report and Considerations: Extended Treatment Options Using the Strategic Implant® and Indications and Objectives for Comprehensive Dental Implant Treatment

Stefan Ihde, Olga Sipic

Department of Evidence and Research, International Implant Foundation, Munich, Germany

## Abstract

While materials for the restoration of teeth and new (digital) technologies develop fast, the choices of the treatment provider and the patients get wider. Choosing an adequate and long-lasting treatment is a question of “doing the right thing,” and only after that, the dentist has to think about the question how to do the work properly. This case report explains and illustrates a case, where an adequate treatment by means of conventional dentistry would not have been possible on one hand, and where treatment with the technology of the Strategic Implant® provided a perfect result within only a few days. Thanks to this technology, patients can be treated with fixed prostheses regardless of the amount of residual bone. Recently, published long-term observations on large amounts of implants have shown that the results are sustainable.

**Keywords:** Alveolar bone reduction, dental implant, immediate functional loading, Strategic Implant®, treatment of periodontally involved cases

## INTRODUCTION

Dental implantology has been a separate specialist discipline within dentistry for >70 years.

Its main indications are the replacement of roots of single, multiple, or all teeth with implants with a view to providing anchorage for fixed or removable dentures. The acceptance of removable tissue-supported dentures has become very low at a time when the chances for success of dental implant treatment and immediate functional loading are ever improving and are now very high.<sup>[1]</sup> In some areas of the jaws, cortically anchored implants provide significantly better results than traditional implant designs.<sup>[2]</sup>

In some countries where obsolete modalities of tooth repair (usually followed by repairs of the repairs) are practiced and paid for or subsidized by social security or health insurance systems, indications for the removal of teeth arise much more frequently than in certain European countries. Where dentistry is very expensive (such as in Switzerland or Austria), patients tend to request early

removal of their own teeth and to be moved to fixed implant-borne restorations in one step. They do this because they know that the constant need to invest into their own teeth for decades will exceed their financial possibilities sooner or later.

Today's dental implantology facilitates significant improvements in facial esthetics. This case report illustrates a treatment that was indicated and codriven by the patient's esthetic demands/request.

Since the vertical bone requirement is very low in the Strategic Implant® technology, the surgeon can level the alveolar bone according to the esthetic requirements.

**Address for correspondence:** Dr. Olga Sipic,  
Desanka Maxsimovic 4, 11000 Belgrade, Serbia.  
E-mail: oljasipic@gmail.com

This is an open access journal, and articles are distributed under the terms of the Creative Commons Attribution-NonCommercial-ShareAlike 4.0 License, which allows others to remix, tweak, and build upon the work non-commercially, as long as appropriate credit is given and the new creations are licensed under the identical terms.

**For reprints contact:** reprints@medknow.com

**How to cite this article:** Ihde S, Sipic O. Dental implant treatment and immediate functional loading (1). Case report and considerations: Extended treatment options using the strategic implant® and indications and objectives for comprehensive dental implant treatment. *Ann Maxillofac Surg* 2019;9:465-9.

### Access this article online

Quick Response Code:



Website:  
www.amsjournal.com

DOI:  
10.4103/ams.ams\_146\_19

## MATERIALS AND METHODS

A 48-year-old male patient, a heavy smoker, requested an overall improvement of his intraoral situation. He complained about difficulties during eating, an unnatural tooth position [Figure 1], and he suffered from compromised esthetics when he smiled [Figure 2]. The panoramic overview picture revealed a hopeless dentition with profound periodontal involvement [Figure 3].

The patient exhibited an angle Class 2 skeletal relationship and a need for substantial adjustment of the hard and soft tissues of both jaws. All teeth required removal. The crestal soft-tissue line (smile line) was determined with the help of intraoral photographs. All teeth in both jaws and the necessary amount of hard and soft tissues were removed under local anesthesia and mild IV sedation (midazolam/propofol/ketamine). Moxifloxacin 400 mg was administered for antibiotic prophylaxis (1 tablet preoperatively and then 1 tablet/day for another 4 days). During the procedure, the field was kept nearly sterile with 5% betadine solution.

After the bone had been leveled, the implants were inserted, and the flaps were closed with 2-0 silk sutures. Impressions of the implants were taken, and the bite was registered. The implants used were BECES Strategic Implants® (Simpladent, Gommiswald, Switzerland) in various lengths and diameters to safely engage the second cortical.

The bridges were fabricated using a reverse design technique. Five hours after the intervention, the setup was tried in, at which the position of all teeth was corrected slightly. The patient was given a chance to test the phonetic and masticatory performance of the future restoration and to judge the esthetic appearance of the bridges. The laboratory technician had used prefabricated teeth for the setup that the prosthodontist and the patient had selected preoperatively. During the try-in, the dentist and the patient can check whether the selected teeth match the patient's facial shape and the midline, whether there is enough space for the tongue, and whether the vertical height is comfortable for the joints and muscles and provides support for the soft tissues.

Based on the model and setup, the framework was designed using the ExoCAD software (ExoCAD GmbH, Julius-Reiber-Straße 37, 64293 Darmstadt, Germany). The resulting STL file with the framework data was then three dimensional printed in composite resin and casted in CoCrMo. The framework was tried in the next morning; adjustments were made to make the framework exactly fit the implants. The sutures were removed at the same appointment. The framework and teeth were connected in the laboratory (using the verticulator). Pink composite was added to fit the gingival line on the model.

The bridges were checked intraorally for proper occlusion and mastication and to inspect the fit of the pink composite relative to the gingiva; any necessary last-minute adjustments were made at this point. The composite bridges

were polish thoroughly. On the 2<sup>nd</sup> postoperative day, the bridges were permanently cemented with Fuji PLUS permanent cement.

## RESULTS

Immediately after the bridges had been cemented, the patient was allowed to eat normally. The first checkup for occlusion and mastication was performed the next day. The rules for the design of the occlusal contacts and masticatory surfaces have been described in Ihde and Ihde.<sup>[3]</sup>

The patient's chewing pattern instantly changed after the insertion of the restorations from a strictly anterior pattern (angle Class 2) to a bilateral pattern.<sup>[4]</sup> No training was necessary to achieve this result that occurred as soon as the anterior blockage caused by the hypererupted teeth had been relieved, an adequate bilateral occlusal surfaces and masticatory slopes had been created, and an acceptable vertical dimension had been achieved.

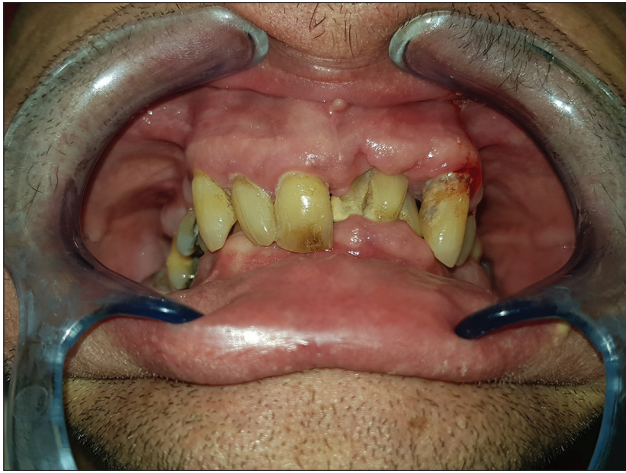## DISCUSSION

The outcome shown here was made possible by the technology of the Strategic Implant®. No other implant system or technology would allow implants in reduced bone, where the first cortical had been completely removed. This technology allows the reconstruction in one step within 2–3 days, depending only on the progress of the work at the dental laboratory. The possibility to complete the treatment in a few days further increases patient acceptance of this treatment.

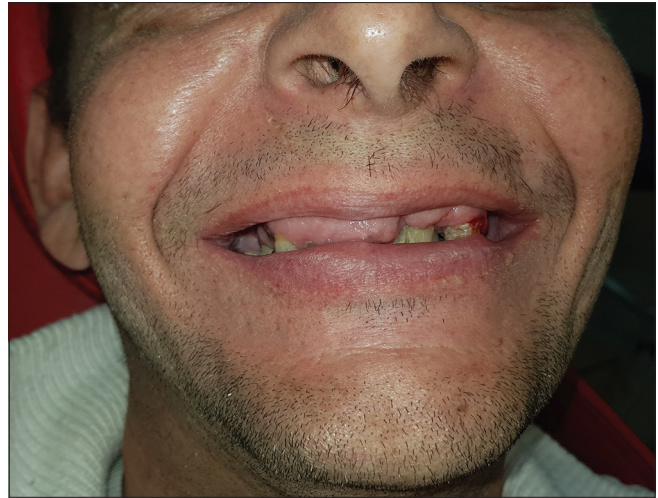A recently published study on the technology has shown that these implants are virtually free of any risk of peri-implantitis. Dobrinin *et al.*<sup>[1]</sup> showed in a large retrospective study of 4095 implants that no peri-implantitis was observed around any of the implants during an observation period of  $19 \pm 8.3$  months. Although 3.1% of the implants failed during the observation period, all cases achieved clinical success (after corrective intervention if necessary). Lazarov<sup>[5]</sup> published data from his private dental implant office on the technology of the Strategic Implant®, showing that also after 4 and more years, this high success rate was observed, and what is more, that no peri-implantitis was found around these implants at all.

This treatment has moved the patient away from the sphere of traditional dentistry and into the care of the dental implantologist.

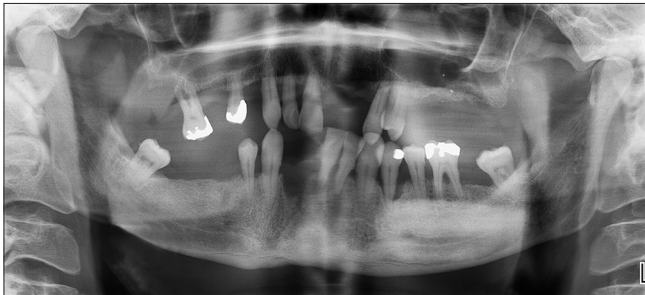This switch of principal treatment provider will not remain unnoticed by conventional dentists, who present all kind of objections and ethical considerations. However, compared to modern implantology, traditional dentistry has little to offer. The authors can jointly look back on 40 years of traditional dentistry and would summarize their experience as follows: most patients (throughout the world) treated by traditional dentistry are on the “downhill road of disappointment” in one way or another all through their lives. Every treatment (however successful) will move them closer to a denture.



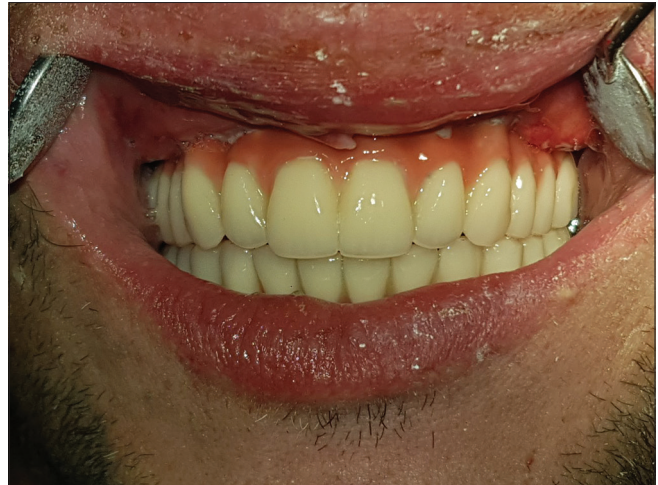**Figure 1:** Intraoral view of the patient preoperatively. Besides the severe angle Class 2 jaw relationship, a remarkable overbite is visible. The upper front segment is severely elongated including the alveolar bone. This means that the alveolar bone will have to be removed to the region of the apex of the front teeth



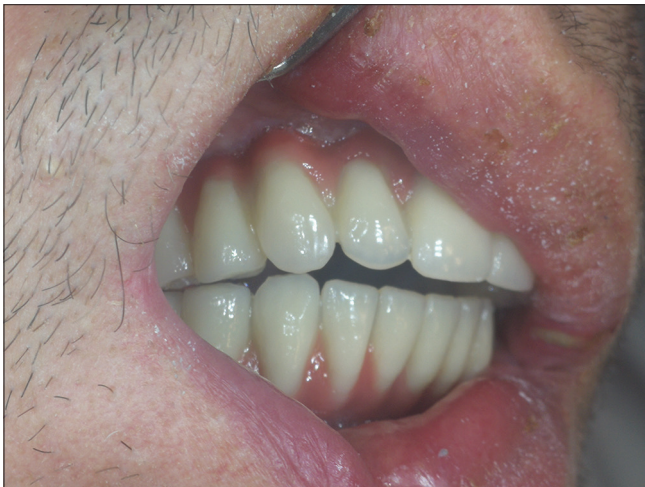**Figure 2:** Preoperative appearance of the patient during smiling. To avoid that the border between the restoration and the patient's gums will be visible, the gum line has to be moved upward significantly



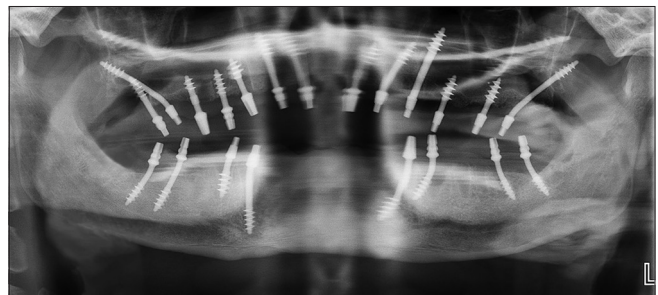
**Figure 3:** Preoperative panoramic overview picture, showing missing teeth, and uneven line of the first cortical in the upper jaw and multiple areas of decay and periodontal involvement. Due to an unfavorable plane of the tomography, we cannot see the elongated bone areas in the upper front



**Figure 4:** Overview on the intraoral situation immediately after fixation of both bridges with permanent cement



**Figure 5:** The surgical and prosthetic treatment had not made changes to the skeletal Class 2 jaw relationship. Since the bite was slightly lifted, the front teeth do not touch, neither in mastication nor in occlusion



**Figure 6:** Postoperative panoramic picture showing the typical distribution of the implants in both jaws for the technology of the Strategic Implant®. All implants were placed according to the standardized methods as defined by the International Implant Foundation IV

Both dentists and implantologists actually recommend implants instead of bridgework because they are

very much aware that the first crowning of a healthy tooth will be the first step on that “downhill road of disappointment.”

The options and the chances for success of conventional dental treatments depend strongly on the vertical positions of the teeth. They determine the bite plane; possibilities of raising or lowering a bite are very limited while the teeth are still in the jaws. The chewing pattern is determined mainly by the vertical positions of (actually only a few) teeth. Many restored dentitions under extended conventional treatment will allow food to be chewed, a smile to be smiled, and other oral functions to be performed. However, if we look closely at those “multi-repaired” dentitions, we will notice that bilateral mastication is hardly possible. Many patients suffer from an untreated unilateral elongation of teeth, resulting in anterior or unilateral chewing patterns. Their jaws cannot move freely during mastication (If our legs were to suffer from similar discrepancies, we would consider ourselves severely handicapped) We, therefore, consider an inability to perform bilateral equal and unlimited mastication as an indication to remove teeth and bone segments that are in the way to restore the full and unimpeded function of the masticatory system. There is no point in “saving” hypererupted teeth or teeth in wrong positions, even if these teeth are superficially “healthy.”

Full and unlimited function of the masticatory system is the primary treatment goal, regardless of whether this is realized on teeth or on implants. Today, we have a choice of what basis to work on. Natural teeth, considering all their disadvantages and their proneness to disease and failure (especially at a more advanced age), are certainly not the preferred foundation for stable and durable occlusal and masticatory surfaces.

The patient described here could have been treated with all kinds of removable dentures, including those attached to the teeth by telescopes, conical crowns, or clasps. The cost of the making such restorations in the dental laboratory is typically higher than the cost of a metal-composite bridge.

The typical chair time for reconstructing both jaws includes the surgery time (45 min/jaw) and the time for the prosthetic treatment steps (2.5 h/case). We can, therefore, state that our treatment is highly effective and requires only very limited chair time. This is one of the reasons why our treatment is cheaper than any other dental treatment, except clasp-retained removable dentures.

This treatment illustrates a simple and an effective way of helping patients to get their ailing dentition removed and to opt for fixed teeth on implants instantly. Many patients in the 40–60-year age group present with dentitions that simply cannot be restored without adding implants to achieve the minimum number of abutments in each jaw. We consider six teeth per quadrant to be a good standard that provides stability of the joints and enough surfaces for chewing.

Traditional dental implantology has been unfortunate in that several impractical dogmas were introduced during the past three decades, such as “placing the implant in the prosthetically

desired position” and “following the concept of the emergence profile.” These ideas guided the whole profession in the wrong direction because they made bone augmentation necessary, and the patients suffer from drawn-out treatment protocols, often spending years in the treatment.

The technology of the Strategic Implant® is aimed at the osseofixation of the load-transmitting implant parts in the corticals, without waiting for “osseointegration.” The concept resembles the technologies used in traumatology and orthopedic surgery. Implants are splinted as early as possible by the prosthetic workpieces, which opens up the possibility of immediate functional loading.

Instead of creating an “emergence profile,” the thin polished vertical parts of the implants (2 mm in diameter) are positioned lingually and palatally, providing great freedom for the dentist technician to create a highly esthetic result [Figures 4-6]. The transition between the natural gingiva and the composite replacement is placed strictly in the invisible zone and hidden by the lips. Hence, no “emerging profile” is required, and the positions of the implants are not dictated by the positions of the crowns.

## CONCLUSIONS

An acceptable esthetic result is possible even in esthetically difficult situations if all teeth in both jaws are removed, and the soft tissues and the bone line are leveled with the intention to move the transition zone upward or downward beneath the lips.

The technology of the Strategic Implant® does not depend on the availability of vertical bone – all it requires is a stable second cortical for implant anchorage to provide a long-term successful function.

The clinically visible teeth are positioned independently of the bone supply and the place of anchorage (strategic positioning of the implants). This makes it easy to create a highly esthetic prosthetic result.

Such an esthetic result is much more easily and predictably achieved by leveling the alveolar bone and removing the superfluous soft tissue than by bone- and soft-tissue augmentation in the esthetic zone.

The primary aim of any dental implant treatment is equal and simultaneous occlusion on both sides as well as bilateral and unlimited masticatory function. Any teeth and any bone segments that would counteract this objective must be removed.

## Declaration of patient consent

The authors certify that they have obtained all appropriate patient consent forms. In the form the patient(s) has/have given his/her/their consent for his/her/their images and other clinical information to be reported in the journal. The patients understand that their names and initials will not be published and due efforts will be made to conceal their identity, but anonymity cannot be guaranteed.

## Financial support and sponsorship

Nil.

## Conflicts of interest

There are no conflicts of interest.

## REFERENCES

1. Oleg D, Alexander L, Vitomir K, Olga S, Damir S, Biljana M. Immediate-functional loading concept with one-piece implants in the mandible and maxilla – A multi-center retrospective clinical study. *J Evol Med Dent Sci* 2019;8:306-15.
2. Ng P, Hu X, Wan S, Mo H, Deng F. Clinical outcomes of bicortical engagement implants in atrophic posterior maxillae: A retrospective study with 1 to 5 years follow-up. *Int J Periodontics Restorative Dent* 2018;38:e96-104.
3. Ihde S, Ihde A. *Cookbook Mastication*. 3<sup>rd</sup> ed. International Implant Foundation Publishing; 2019. ISBN 987-3-945889-12-1.
4. Ihde S. *Principles of BOI*. Heidelberg: Springer Verlag; 2004.
5. Lazarov A. Immediate functional loading: Results for the concept of the strategic implant®. *Ann Maxillofac Surg* 2019;9:78-88.