

Functional and Esthetic Indication for Dental Implant Treatment and Immediate Loading (2) Case Report and Considerations: Typical Attitudes of Dentists (and their Unions) toward Tooth Extractions and the Prevention of Early, Effective, and Helpful Dental Implant Treatment in the European Union

Stefan Ihde, Olga Sipic

Department of Evidence and Research, International Implant Foundation, Munich, Germany

Abstract

The technology of the Strategic Implant® facilitates dental implant treatment almost regardless of the available bone. This explains its increasing use to resolve problems with the dentition of the middle-aged patient in a radical manner, simply by extracting the residual dentition and placing implants. While a radical change in the implant treatment paradigm has taken place in some countries, in other countries, dentists try hard to keep their work area free of implants or to deliver them only as a last resort. Liberating patients from the burdens of their own teeth are not advocated by dental universities, as their main field of teaching deals with the repair of teeth and conventional ways of replacing them. This case report shows a standard treatment with Strategic Implants®, discussing the topic from the point of view of practitioners, universities, and other parties involved in decision-making. The authors conclude that the interests of the patients are not respected in many cases because the parties involved have vested interests in other treatment modalities.

Keywords: Alveolar bone reduction, corrected vertical positions of anterior teeth, dental implant, immediate functional loading, Strategic Implant®

INTRODUCTION

Dental implantology has been a separate specialist discipline within the dentistry for more than 70 years.

Its main indications are the replacement of roots of single, multiple, or all teeth with implants with a view to providing anchorage for fixed or removable dentures. The acceptance of removable tissue-supported dentures has become very low at a time when the chances for success of dental implant treatment and immediate functional loading are ever-improving and are now very high.^[1] In some areas of the jaws, cortically anchored implants provide significantly better results than the traditional implant designs.^[2]

As soon as partially edentulous patients are ready for full-arch extraction in both jaws, the implantologist has the chance to determine the position of the new teeth independently of

the old (extracted) teeth.^[3] Besides the demand for a correct bite plane, it is mainly esthetics that guides decisions in this situation. While in conventional dental implantology the available amount of vertical bone is a critical parameter for the treatment, in corticobasal implantology, only the availability of cortical bone (namely the 2nd cortical) is relevant.^[4]

Today's dental implantology facilitates significant improvements in facial esthetics. Edentulous patients who opt for implant therapy have more and better choices regarding their tooth

Address for correspondence: Dr. Olga Sipic,
Desanka Maksimovic 4, 11000 Belgrade, Serbia.
E-mail: oljasipic@gmail.com

This is an open access journal, and articles are distributed under the terms of the Creative Commons Attribution-NonCommercial-ShareAlike 4.0 License, which allows others to remix, tweak, and build upon the work non-commercially, as long as appropriate credit is given and the new creations are licensed under the identical terms.

For reprints contact: reprints@medknow.com

How to cite this article: Ihde S, Sipic O. Functional and esthetic indication for dental implant treatment and immediate loading (2) Case report and considerations: Typical attitudes of dentists (and their unions) toward tooth extractions and the prevention of early, effective, and helpful dental implant treatment in the European union. *Ann Maxillofac Surg* 2019;9:470-4.

Access this article online

Quick Response Code:



Website:
www.amsjournal.com

DOI:
10.4103/ams.ams_152_19

positions compared to more or less edentulous patients. One of the reasons is that implant-supported dentures typically do not only replace the teeth but also the part of the gingiva. In this way, a beautiful transition between the new teeth and the gingiva can be purposefully achieved in a well-equipped dental laboratory. Here too, corticobasal implants have clear advantages over conventional dental implants, which demand the development of an emergence profile and often a number of additional soft-tissue interventions.

This case report illustrates a treatment that was indicated and codriven by the patient's esthetic demands/request.

MATERIALS AND METHODS

A 52-year-old male patient, heavy smoker, requested an overall improvement of his intraoral situation and healthy fixed dentition. He complained about difficulties in eating, an unnatural tooth position and heavily restored upper anterior with frequent fractures of fillings [Figure 1], and suffered from compromised esthetics when smiling [Figure 2].

The patient exhibited an angle Class 2 skeletal relationship and a need for substantial adjustment of the maxillary hard and soft tissues for an esthetic result. All teeth required removal. The crestal soft-tissue line (smile line) was determined and registered with the help of en-face photographs of the smiling patient. All teeth in both jaws and the necessary amount of hard and soft tissues were removed under local anesthesia. Moxifloxacin 400 mg (1 tablet preoperatively and then 1 tablet/day for another 4 days) and a single dose of fluconazole 150 mg were administered for antibiotic prophylaxis. During the procedure, the field was kept nearly sterile with 5% Betadine solution.

After the bone had been leveled, the implants were inserted, and the flaps were closed with 2–0 silk sutures. Impressions of the implants were taken, and the bite was registered. The implants used were BECES Strategic Implants® (Simpladent, Gommiswald, Switzerland) in various lengths and diameters to safely engage the second cortical.

The bridges were fabricated using a reverse design technique. Shortly after the intervention, the setup was tried in. The patient was given a chance to test the vertical dimension and the phonetic and (to some extent) masticatory performance of the future restoration and to judge the esthetic appearance and dimensions of the bridges, which he approved.

Digital workflow was used to fabricate the metal framework for try-in on the next day. The composite teeth and the metal framework were connected immediately afterwards and pink resin was added to adapt the gingival gaps and to provide an esthetic appearance.

The bridges were checked intraorally for proper occlusion and mastication and precured with standard light-curing devices and then polished thoroughly. On the 3rd postoperative day, the bridges were permanently cemented with GC Fuji Plus permanent cement.

RESULTS

Immediately, after the bridges had been cemented, the patient was allowed to eat normally. The first checkup for occlusion and mastication was performed the next day. The rule for the design of the occlusal contacts and masticatory surfaces have been described in Ihde and Ihde,^[5] whose rules were followed meticulously.^[6]

The patient's chewing pattern instantly changed after the insertion of the restorations from a strictly anterior pattern (Angle Class II) to a bilateral pattern.^[7] No training was necessary to achieve this result. As soon as the anterior blockage caused by the hyper erupted teeth had been relieved, adequate bilateral occlusal surfaces and masticatory slopes had been created and an acceptable vertical dimension had been achieved, the pattern of chewing becomes bilateral, as is normal in humans. Engrams for both patterns of chewing are present from the early youth, which allows the patients to switch to (regular) bilateral function instantly.

DISCUSSION

The outcome shown here was made possible by the technology of the Strategic Implant®. No other implant system or technology would allow implants in the reduced bone where the first cortical had been completely removed. This technology allows the reconstruction in one step within 2–4 days, depending only on the progress of the work at the dental laboratory. The possibility to complete the treatment in a few days further increases the patient acceptance of this treatment and completely justify the “dental tourism” certain patients embark on.

A recently published study on the technology has shown that these implants are virtually free of any risk of peri-implantitis. In a large retrospective study of 4095 implants, Dobrinin *et al.*^[1] showed that no peri-implantitis was observed around any of the implants during an observation period of 19 ± 8.3 months. This makes it easy to decide to insert an abundant number of implants. Lazarov demonstrates in a large study done in his private clinic that the Strategic Implant® seems to be resistant to peri-implantitis and that the success rate for these implants and the technology connected to it remain high and virtually stable over 4 and more years.^[8]

The question remains why a patient with sufficient funds for implants, living in Central Europe (France) is in such a disastrous state of oral “health” while being surrounded by 345,000 licensed European Union (EU) dentists.

There are a number of answers to this question.

1. Traditional dentistry on teeth does not provide/offer an acceptable treatment for patients in whom the destruction of the dentition has progressed to the point shown in Figure 3. Whatever traditional dentistry would attempt would resolve neither the esthetic problems nor the problems of insufficient masticatory function. Patients are (unfortunately) trained from early childhood to see a dentist when problems occur in their oral cavity. As a

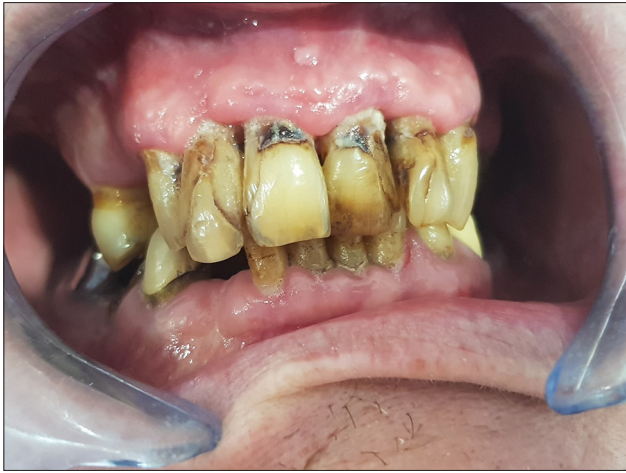

Figure 1: Preoperative intraoral view of an Angle Class 2 jaw relationship and a severe overbite. The maxillary anterior segment is severely elongated, as is the alveolar bone. Deep pockets with putrid exudates were found in all quadrants

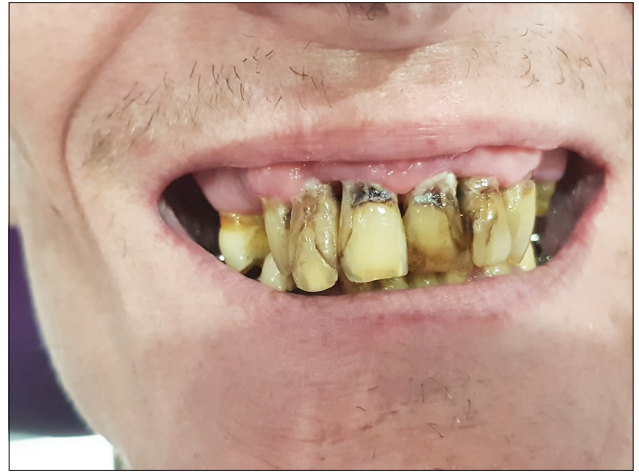

Figure 2: Preoperative appearance of the patient's normal smile

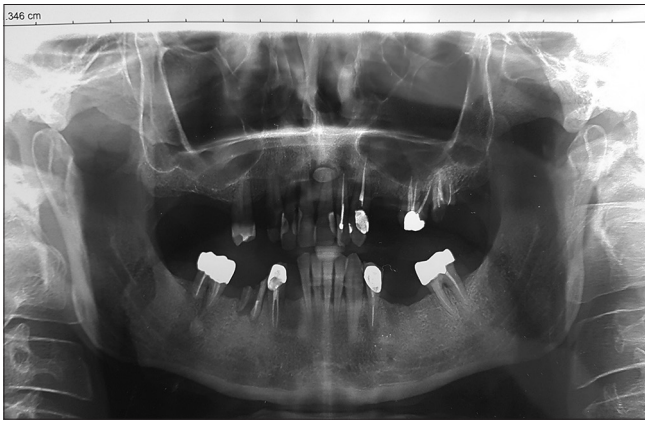


Figure 3: Preoperative panoramic radiograph showing edentulous spaces, profound periodontal involvement, teeth with paro/endo defects, root resorptions, and incomplete root-canal treatments. In this image (tomography), the elongation of the maxillary anterior bone segment is not visible. Certainly, it would be possible to repair single teeth for a number of times still. The “big picture” however shows that bilateral and equal mastication on teeth is not possible if these teeth are used

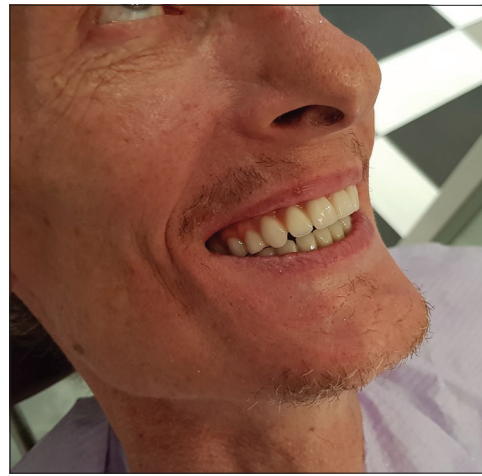

Figure 4: Intraoral situation immediately after permanent cementation of the two bridges

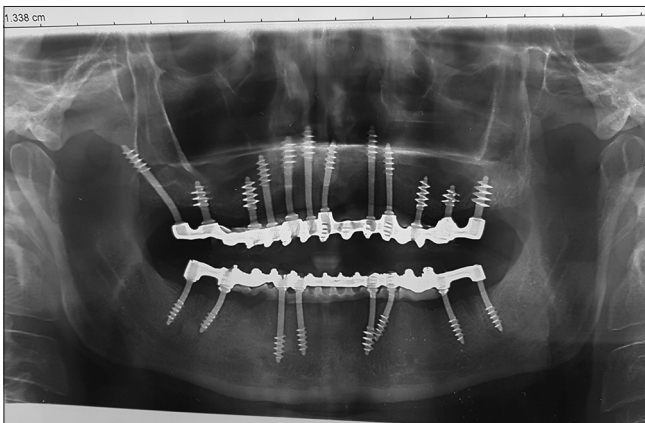


Figure 5: Postoperative panoramic radiograph showing typical distribution of the Strategic Implants® in both jaws. All implants were placed according to the IF methods defined by the International Implant Foundation

- matter of fact, patients with such a disastrous dental status cannot expect adequate help today at a dentist's office
2. Traditional dentistry on teeth does not even briefly provide hope for bilateral equal mastication on fixed teeth for this patient
 3. Conventional dental implantology would require extractions followed by socket-healing periods, in turn, followed by the placement of implants. The overall treatment time in which the patient goes without fixed teeth will be at least 6 months
 4. For unknown reasons, the average cost for conventional dental implant treatment for both jaws is enormous. Patients pay more for dental implant therapy than for regular dentistry (this is not justified because the chair time for an implant solution is shorter than for a tooth-supported restoration for this patient, and the demand for precision in the dental laboratory is less exacting than for tooth-supported restorations).

As this example shows, the Strategic Implant® technology resulted on acceptable esthetics and fixed teeth within a few days.

While this patient opted for treatment with the Strategic Implant® right away, reasons 1–4 above (and maybe additional reasons) had prevented conventional implant treatment for many years.

The patient understood a long time ago that his principal esthetic problem would never be resolved until and unless (at least from his point of view) the upper anteriors (or preferably all maxillary teeth) had been removed. However, no dentist was ready to do this. Every dentist he consulted only talked about “saving” the teeth and repairing them. This made no sense to the patient; he gave up seeing dentists, which did not understand his needs and his problems anyway. The patient had concluded that not a single one of 345,000 dentists in the EU would be willing or able to help him. He, therefore, went abroad to consult highly specialized treatment providers, which do not work within the “system.”

It is actually easy to speculate why those dentists did not offer any help. Here are some of the putative reasons:

- Dentists are trained to repair teeth. This is their primary job. Once their clientele no longer has any teeth, their income situation will deteriorate
- If there is only a small number of teeth left, they proceed to creating more or less complicated dentures, which should be partly tooth supported as long as possible (according to a traditional dentist’s thinking)
- Every removal of a tooth potentially eats away at a dentist’s future income. The worst-case situation is reached once two full dentures are delivered because these two dentures will virtually last forever and cost next to nothing
- Patients are therefore being told throughout life that it is important to save every single tooth for as long as possible to “provide retention” for a future denture
- Patients rarely realize at that stage of their lives that they will anyway never be willing to wear a removable denture, nor do they understand that their meticulously “saved” teeth do not help at all as soon as a certain level of breakdown of their dentition has happened (and that happens sooner than one would imagine). Only fixed teeth (on natural teeth or on implants) provide resistance to masticatory forces
- Obviously, the vast majority of today’s dentists in many countries act on the basis of outdated (from a technical point of view) parameters, objectives, and beliefs. Moreover, as a result, a large number of patients in the European Union remain untreated
- It should also be mentioned that our treatment, while it has helped the patient a lot, has hurt the income situation of an unknown number of dentists. Overall, those dentists have lost much more money than we charged patient. If this happens, it can actually be detrimental to the spreading of a given technology, especially in highly regulated health systems or in health systems where the market of (conventional) dental implants is held captive by a few surgeons
- Dentists in most countries prefer to insert complex designs on teeth (tooth-supported crowns, conical crowns, and

telescopes combined with intricate dentures) because the financial rewards are considerable and because these designs can be sold to a segment of the population that can well afford it

- Surgically oriented practitioners, more specifically maxillofacial surgeons, are “by nature” not interested in simple dental-implant solutions because they generate at least 30% of the implant-related income by adding “bone augmentation” to the treatment plan. In fact, this interest group loses most of its business with the appearance of the technology of the Strategic Implant®: Bone-block transplants were previously their domain, and typically, the adjacent implant therapy was performed by them as well. The technology of the Strategic Implant® places implantology as such back in the hands of the specially trained dentist-implantologist
- It should also be mentioned here that practical and effective dental implantology is not taught at any university in the EU at present.

As Figures 1 and 2 clearly show, the hypererupted maxillary teeth and the elongated upper anterior bone segment were causing major esthetic problems. Without removing both the bone and the upper anteriors, acceptable esthetics would not have been achievable possible. There is no point in “saving” hypererupted teeth or teeth in wrong positions, even if these teeth are superficially “healthy.”

Hypererupted anteriors not only block lateral mandibular movements but also predispose the patient for an anterior chewing pattern – both unnatural and deleterious to oral health.

We consider the possibility for unlimited bilateral mastication a prerequisite for the functional health of the masticatory system. If this aim is not reached, no prosthetic rehabilitation, whether on teeth or on implants can be successful in the long term.

This treatment illustrates a simple and effective way of helping patients to get their ailing dentition removed and to opt for fixed teeth on implants instantly. Many patients aged 40–60 years present with dentitions that simply cannot be restored by dentists – these patients have to see an experienced implantologist.

During the past two decades, two different technologies have developed regarding dental implants:

- Conventional dental implantology, as promoted by a number of universities
- Corticobasal implantology (the concept of the Strategic Implant®), a technology that is much more effective than any other concept within dental implantology.

Traditional dental implantology has been unfortunate in that several impractical dogmas were introduced during the past three decades, such as “placing the implant in the prosthetically desired position” and “following the concept of the emergence profile.”

Similarly, the belief that specific implant surfaces are better than others and the whole concept of osseointegration are – from the point of view of what we know today – a curse than of any help.

The assumption that some specific implant surface works better than polished titanium is not justified by science. It is simply a “story” made up by large implant manufacturers. Especially, the universities keep on being staunch believers in “osseointegration,” and they do this because influential people there get paybacks from the manufacturers. Even individual surgeons frequently get such paybacks from the implant manufacturer (or a local distributor) – the money comes right back in with every implant which he/she places. Moreover, this is exactly why the surgeon places a given implant rather than a better one.

All those ideas and developments have taken the whole profession on a detour in the wrong direction. Conventional dental implants with all their disadvantages have given justification to bone augmentations, making patients suffer even more from these drawn-out treatment protocols, and often spending years in the treatment.

All this is unnecessary today if the technology of the Strategic Implant[®] is used. It aims at the osseofixation of the load-transmitting implant parts in the corticals, without waiting for “osseointegration.” The concept resembles the technologies used in traumatology and orthopedic surgery for more than 50 years. In specific situations, immediate loading is still possible and successful even for single implants or single-tooth replacements (with more than one implants).

Instead of creating an “emergence profile,” the thin-polished vertical parts of the implants (2 mm in diameter) are positioned lingually and palatally, providing great freedom for the dentist technician to create a highly esthetic result [Figures 4 and 5]. The transition between the natural gingiva and the composite (acrylic or even ceramic) replacement is placed strictly in the invisible zone and hidden by the lips. Hence, no “emerging profile” is required, and the positions of the implants are not dictated by the positions of the crowns.

CONCLUSIONS

1. Even in initially difficult situations, an acceptable esthetic result can be achieved if all teeth in both jaws are removed and the soft tissues and bone line are leveled with the intention to move the restoration/gingiva transition zone upward in the maxilla or downward in the mandible
2. The technology of the Strategic Implant[®] does not depend on the availability of vertical bone – all it requires is a stable second or third cortical for implant anchorage
3. The clinically visible teeth are positioned independently of the bone supply and the place of anchorage (strategic positioning of the implants). This makes it easy to create a highly esthetic prosthetic result
4. Such an esthetic result is much more easily and predictably achieved by leveling the alveolar bone and removing superfluous soft tissue than by bone and soft-tissue augmentation in the esthetic zone
5. The primary aim of any dental implant treatment is equal and simultaneous occlusion on both sides as well as bilateral and unlimited masticatory function. Any teeth and any bone segments that would counteract this objective (and prevent its maintenance) must be removed because they would prevent a treatment that would meet the patient’s expectations
6. Complex treatments combining fixed restored teeth and removable dentures must be absolutely avoided. The treatment plan for humans should always aim at creating and maintaining fixed teeth throughout life. This is also cheaper than the fabrication of complex restorations
7. In many countries, various illegal financial arrangements between implant manufacturers and their distributors impede progress in dental implantology and prevent the profession from moving in the direction the user would like to see
8. It seems that in the field of dental implantology, none of the parties involved is ready to respect the interests of the patients. Unless this professional negligence is corrected, unhealthy developments in the society at large will be the inevitable result.^[9]

Declaration of patient consent

The authors certify that they have obtained all appropriate patient consent forms. In the form the patient(s) has/have given his/her/their consent for his/her/their images and other clinical information to be reported in the journal. The patients understand that their names and initials will not be published and due efforts will be made to conceal their identity, but anonymity cannot be guaranteed.

Financial support and sponsorship

Nil.

Conflicts of interest

There are no conflicts of interest.

REFERENCES

1. Dobrinin O, Lazarov A, Konstantinovic VS, Sipic O, Siljanovski D, Milicic B. Immediate-functional loading concept with one-piece implants (BECES/BECES N/KOS/BOI) in the mandible and maxilla- a multi-center retrospective clinical study. *J Evolution Med Dent Sci* 2019;8:306-15.
2. Ng P, Hu X, Wan S, Mo H, Deng F. Clinical outcomes of bicortical engagement implants in atrophic posterior maxillae: A retrospective study with 1 to 5 years follow-up. *Int J Periodontics Restorative Dent* 2018;38:e96-104.
3. Ihde S, Sipic O. Dental implant treatment and immediate functional loading (1). Case report and considerations: extended treatment options using the strategic implant[®] and indications and objectives for comprehensive dental implant treatment. *Ann Maxillofac Surg* 2019;9:465-9.
4. Ihde S, Ihde A, Lysenko V, Konstantinovic V, Palka L. New systematic terminology of cortical bone areals for osseo-fixed Implants in strategic oral implantology. *JJ Anat* 2016;1:7.
5. Ihde S, Ihde A. *Cookbook Mastication*. 3rd ed. Munich, Germany: International Implant Foundation Publishing; 2019.
6. International Implant Foundation: Consensus on 16 Methods for the Placement of Basal Implants. Available from: <http://implantfoundation.org/en/consensus-16-approved-methods-2018-menu-en>. [Last seen 2019 Aug 26].
7. Ihde S. *Principles of BOI*. Heidelberg: Springer Verlag; 2004.
8. Lazarov A. Immediate functional loading: Results for the concept of the strategic implant[®]. *Ann Maxillofac Surg* 2019;9:78-88.
9. Olson M. *Rise and Decline of Nations*. New Haven, Connecticut, USA: Yale University Press; 1982.