

Immediate Functional Loading: Results for the Concept of the Strategic Implant®

Aleksandar Lazarov

Private Oral Implant Center Aldent, Sofia, Bulgaria

Abstract

Background: Immediate functional loading of one-piece dental implants has become an accepted treatment modality for fixed restorations in fully edentulous mandibles and maxillae. Nevertheless, studies regarding immediate loading procedures in extraction sites in both the jaws, as well as in segment reconstructions and single-tooth replacements, are limited. **Purpose:** The purpose of this study was to evaluate the presently used protocol for immediate functional loading (within maximum 3 days) of one-piece implants which are placed according to the following methods as published by the IF. **Materials and Methods:** This prospective cohort study included totally 87 consecutively treated patients who receive 1169 immediately loaded one-piece Strategic Implant®, supporting fixed complete-arch maxillary or mandibular metal-ceramic bridges or segment reconstructions in both the jaws. All implants were placed by one treatment provider, who delivered also the prosthetics and controlled all cases himself over the years. Data were extracted by an experienced dentist from the patient records and from panoramic X-rays. A number of patients were interviewed at the end of the observation period. Although a total of 5100 implants were placed and observed for 12 – 57 months totally (with 105 implants out of these, having failed), this article reports the detailed results only for 1169 implants which have been followed for at least 48 months. **Results:** Immediate functional loading of using multiple, cortically anchored basal screw implants as a support for fixed full-arch and segment prosthesis in the upper and lower jaw demonstrated a high cumulative implant survival rate after an observation period of up to 57 months. Neither hypertension nor diabetes and neither smoking nor bending of the implant's neck had an influence on the success of the implants observed in this study. Within the limits of this study (5100 Strategic Implants were observed over a period of up to 57 months), “peri-implantitis” was not observed at all. **Conclusion:** The treatment concept developed for the technology of the Strategic Implant® is safe and effective and it avoids bone augmentations and “peri-implantitis”.

Keywords: Bendable implant necks, complete arch reconstruction, immediate functional loading, prospective study, segment reconstruction, Strategic Implant®

INTRODUCTION

Immediate/early implant loading procedures are well documented in cases of the edentulous mandible and the maxilla.^[1,2] Implant anchorage in the totally edentulous maxilla is in many regions frequently restricted due to bone resorption (atrophy), which is especially frequent in the posterior region of the maxillary arch. Bone grafting is according to the traditional concepts often performed in such cases. The use of implant tilting in the maxilla has been demonstrated to be an alternative to bone grafting.^[3,4] By distal tilting of distal implants in the arch, a more posterior implant and abutment position can be reached, for example, in the “All-on-4 concept.” At the same time, an improved implant anchorage can be achieved using the cortical bone of the wall of the sinus and the nasal floor.^[5] In the concept used, however, the abutments of the distal implants are anchored

in the tuberopterygoid region in both the jaws into mesial direction (Method 9). In the distal mandible, the lingual cortical undercuts of mandible were target (second/third corticals (Method 5)).

Bending the necks of dental implants lead to internal stresses in the area of the implant shaft, and the process of bending the inserted implants will impose enormous forces onto the bone. Assuming that all other parameters are equal, bendable (basal) implants show a more even stress distribution along the vertical implant region than identically shaped implants with

Address for correspondence: Dr. Aleksandar Lazarov,
Private Oral Implant Center, Sofia, Bulgaria.
E-mail: alex.lazarov@yahoo.co.uk

This is an open access journal, and articles are distributed under the terms of the Creative Commons Attribution-NonCommercial-ShareAlike 4.0 License, which allows others to remix, tweak, and build upon the work non-commercially, as long as appropriate credit is given and the new creations are licensed under the identical terms.

For reprints contact: reprints@medknow.com

How to cite this article: Lazarov A. Immediate functional loading: Results for the concept of the strategic implant®. Ann Maxillofac Surg 2019;9:78-88.

Access this article online

Quick Response Code:



Website:
www.amsjournal.com

DOI:
10.4103/ams.ams_250_18

a machine-angulated area. Therefore, bendable basal implants probably resist masticatory forces better than preangulated, machined implants, and even better than unbent implants which provide a thin region in the vertical implant area.^[6]

The purpose of this study was also to evaluate after up to 57 months a treatment protocol in immediate functional loading for fixed complete-arch prostheses, segment reconstructions, and single implants in the completely edentulous mandible and maxilla supported by cortically anchored implants and to evaluate implant success rate for those implants, where the abutment heads were parallelized through bending after implant placement.

It is sometimes advocated that two-stage implantology has been “forever” supported by randomized controlled clinical trials. Today, we know, however, that a large amount of studies published even in high-class journals (PubMed listed and with impact factor) have to be considered simply as wrong.^[7,8] Furthermore, we have to accept the fact that a randomized controlled clinical trial including the concept of the Strategic Implant® (compared to conventional two-stage implants) is technically impossible to do because in the two-stage group, the vast majority of patients is not eligible for these implants at all (the will drop out from the beginning), or bone augmentation must be included into the treatment protocol. Hence, prospective studies (like this one) or retrospective cohort studies are the best, we can possibly get by means of modern science.

MATERIALS AND METHODS

Patient characteristics

In this study, all 87 consecutively treated patients who received treatment from the day of the opening of a new implantological center were included into the study. Forty-two of them (48.3%) were male and 45 (51.7%) were female; the average age of patients was 54.18 + 10.08 years. About 20.8% of the patients were suffering from hypertension. Nearly 5.7% of the patients suffered from diabetes. About 30.2% of the patients were smokers [Table 1].

Implant characteristics

For the treatment of the patients, three different types of implants were utilized according to the preference of the treatment provider in the individual case [Table 2].

All implants, which were used in this study, provided the possibility for bending in the neck area to align the direction of the abutment head for easier insertion of the prosthesis.

The clinic from where all data were obtained had been founded with the intention to provide dental implant treatment in an immediate loading protocol. The clinic does not provide other treatments, except if they would become necessary in combination with the implant treatment, for example, to raise bites, provide adequate chewing surfaces in the opposing jaw (not treated with implants), etc., This is a prospective study, as it had been planned from the moment when the clinic was

opened, to regularly report on various aspects of the treatment over time. For this purpose, a large amount of data were collected and used later for the observations. The treatment provider had been educated specifically for the work with the Strategic Implant® and achieved the “Master of Immediate Loading” degree. No patient was rejected for treatment except if the patient refused to undergo a comprehensive treatment plan with the intention to provide six fully functional teeth in each quadrant with the curves of Spee and Wilson created in an ideal manner and the plane of bite being parallel to the plane of Camper. Neither one single patient was rejected for “lack of bone” nor for any diseases that he carried. Three patients who had received earlier IV-bisphosphonate treatment in their medical history were however rejected. All other patients requesting treatment (also those which had received oral bisphosphonates) were treated if they agreed to the treatment plan and this plan followed the 16 acknowledged methods

Table 1: Patient characteristics

Observed parameters	n (%) / (X ± SD; [median; minimum-maximum])
Number of patients	87
Number of implants	1169
Number of implants in full function	1138 (97.3)
Age	54.18 ± 10.08 (55.0; 22-72)
Gender	
Male	42 (48.3)
Female	45 (51.7)
Hypertension	
Yes	2 (2.3)
No	85 (97.7)
Diabetes mellitus	
Yes	5 (5.7)
No	82 (94.3)
Smokers	
Yes	26 (30.2)
No	60 (69.8)

SD: Standard deviation

Table 2: Location and usage of implants

Implant and placement characteristics	n (%)
Type of implant	
BECES/BCS (Strategic Implant®) (screwable cortical implant)	1019 (87.1)
KOS (compression screws)	142 (12.2)
KOS plus (combination implant)	6 (0.5)
BOI (lateral basal implant)	2 (0.2)
Implant location (jaw)	
Maxilla/mandible	663 (56.7)/506 (43.3)
Yes/no	524 (44.8)/645 (55.2)
Implant shafts bent after placement for parallelization	
Yes/no	388 (33.2)/782 (66.8)

for placement of the Strategic Implant® as published by the International Implant Foundation.^[9]

Implants were placed in the locations as shown in Table 3.

Very few patients refused the treatment because they could not afford it. These patients and their implants were not recorded, nor were the nonplaced implants counted as failure, which in a way, violates the “Intention-to-Treat Principle.” For example, if a sinus lift procedure fails, which was done with the intention of placing later three implants, all these three implants should be counted as failure when it comes to report on the treatment as a whole.

Criteria of success and failure and data acquisition

Criteria of possible failure were noted as follows: the existence of “discomfort,” radiologically observable bone loss.

Criteria for survival and success were as follows: No pain, no mobility, no detectable infection, observed/reported, and no bone loss visible on the panoramic picture. All implants were placed in local anesthesia and with the primary aim of anchoring the load transmitting apical (basal) threads in resorption free second/third corticals (for screwable cortical implants) or horizontal bi-cortical support (for lateral basal implants) regardless of the parallelity between the heads of the implants. Compression screw implants were rigidly anchored through compression of trabecular bone areas and in the first cortical. The patients were asked to turn up for follow-up examinations regularly. Not all patients appeared that regularly over the full observation period; however, if they did appear later on for control during the observation period, they were not left out from the study and their last control appointment became their date of last control. All patients who were ever treated in the clinic were enrolled automatically into the study; however, not all patients were available for a clinical or radiological inspection when data were collected for this study. Hence, the reported outcome is based on different observations: X-ray control, clinical inspection, and report of the patient through E-mail or in a phone interview on the following questions:

- Do you feel any pain or discomfort in connection to your implants?
- Can you eat all the food which you would like to eat without any limitations?
- Are you limited in your social or private life due to problems with your teeth/bridges?
- Did your speaking function change and were you able to adapt your speaking function?

On X-rays, the following parameters were observed:

- The marginal bone level close to the implants shaft on the panoramic overview picture
- The integration of the load transmitting parts of the implants observed through the visible direct contact between bone and the vertical implant part on the radiograph
- The radiologic observation of the healing of the sockets containing implants.

Technique and treatment protocol

In both the jaws, the implants were placed with the primary aim of cortical anchorage of the load transmitting thread at least in the second/third cortical.^[10] Implants were inserted into fresh extraction sockets even in cases when profound periodontal involvement and/or periapical osteolysis was present before tooth extraction [Table 15]. As an alternative to cortically anchored screw implants, compression screw implants in the upper and lower jaw were inserted with the primary aim of achieving stability through compression of trabecular bone along the vertical (endosseous) axis of the implant. Compression screws were never inserted into extraction sockets. It was left fully to the decision of the treatment provider, which implant type would be used in the individual patient and at which individual site. The clinic had a sufficient stock of all types of implants on hand, to suit all clinical situations. None of the implants were placed with the help of surgical guides. Treatment was provided on the base of panoramic pictures or computed tomography data.

In all cases, the implants were splinted with a first fixed stable bridge (circular or segmental) within maximum 72 h. Implants for the replacement of a single tooth (with one or two implants) were equipped either within the same period with a fixed crown. Segment bridges and full bridges in both the jaws were installed in full functional loading^[11] [Table 4].

The prosthetic workpieces were created by following the concept which Ihde and Ihde had outlined.

All bridges consisted of a metal frame and veneering from ceramics. They were considered as permanent bridges even if some bridges were exchanged later for various reasons.

Table 3: Place of insertion and type of anchorage for all implants within this study

Place of insertion in the second cortical (target cortical)	n (%)
Floor of nose	321 (27.4)
Sinus floor	177 (15.1)
Palatal	50 (4.3)
Tuberopterygoid	117 (10.0)
Mandible interforaminal anchorage	212 (18.1)
Distal mandible anchorage without cortical engagement	123 (10.5)
Cortical distal mandible	169 (14.5)

Table 4: Type of prosthetic constructions on all implants

Amount of implants in different prosthetic constructions	n (%)
Construction	
Full bridge upper	612 (52.3)
Full bridge lower	438 (37.5)
Segment upper	47 (4.0)
Segment lower	70 (6.0)
Single teeth	2 (0.2)

Replacements of bridges were not investigated in this study; however, if during bridge replacement also implants had to be replaced (e.g., due to vertical mobility, fracture of metal frame or ceramics, or due to gaps developing between the bridge and the healed mucosa in extraction cases), the lost implants were considered as failed. The new implant did not enter the study. Removal of implants was in most cases done during routine replacements of first provisional bridges. If enough stable implants were left for holding the construction, single mobile implants were removed and no replacement implants were inserted.

The prosthetic concept included occlusal contacts on both premolars and the anterior half of the first molar but not distally to this area and not on the frontal group [Figure 1]. A typical treatment plan and its radiological and clinical result is shown in Figures 2-5.

The position and orientation of the implants was characterized in two different ways:

The point of penetration in the first cortical was noted with the usual tooth positions 11-48. The point of anchorage on the implant's thread in the 2nd/3rd cortical (target cortical) was chosen by the surgeon independently of the point of insertion into the first cortical or the extraction socket. Many implants were intentionally placed not vertically (tilted) in all areas of the jaws. Tilting was done in all directions (either in lingual, vestibular, palatal in medial direction). In the upper jaw, three different anchorage regions were recorded: the floor of the nose for 321 (27.4%) implants, the floor of the sinus for 177 (15.1%), the bone areas palatal to the maxillary sinus for 50 (4.3%), and the pterygoid plate of the sphenoid bone for 117 (10%). Likewise, in the mandible, interforaminal anchorage for 212 (18.1%) was utilized. In the distal mandible, anchorage without cortical engagement (i.e., with compression screws) was chosen for 123 implants (10.5%), while second cortical anchorage for 170 implants was achieved (14.5%) [Table 5]. For KOS-series of implants, the second cortical anchorage is not mandatory.

If teeth were extracted during the same appointment during which the implants were placed, it was noted if the placement was done into healed jaw bone or the fresh sockets. Furthermore, it was assessed radiographically during the 12-month radiographic control appointment, if the sockets with the implants inside had filled with mineralized tissue, that is, if the vertical bone growth along the implant took place so that the socket healed uneventfully more or less to the previous (preoperative) bone level and mineralization.

Statistical methods

To assess the survival and success rate of the implants, pairwise comparison and log-rank test were applied. Computation of data was done through SPSS program, ver 25 (Manufacturer: IBM Corp., Armonk, NY, USA).

RESULTS

Patient characteristics

No patient was withdrawn later from the study, and all 87 patients (with 1170 immediately loaded implants) were followed for up to 57 months. If patients passed away during the observation period, their implants and constructions were counted as successful until the month during which they passed away, that is, their implants remained in the statistics in the same month while others continued "aging." The implants of these patients did not drop out from the study.

In this study, patients who had missed one or several control appointments were not excluded. All patients were at least interviewed at the end of the observation period.

Very few patients refused the treatment because they could not afford it. These patients and their implants were not recorded, nor were the nonplaced implants counted as failure, which in a way, violates the "Intention-to-Treat Principle." For example, if a sinus lift procedure fails, which was done with the intention of placing later three implants, all these three implants should be counted as failure when it comes to report on the treatment as a whole. Likewise, if a patient without sufficient funding requests treatment of both the jaws with dental implants, the treatment which (due to the lack of funding) did not take place could be considered as a failure because it was not available for all of the population but only for a selected group of patients.

Survival rate of implants and success rate of prosthetic work

Success rate and implant length

Differences were found in the success rate if different lengths and diameters of implants were compared [Tables 7-10].

Types of follow-up/end-point for each patient

Not all patients had decided to follow the treatment providers' advice for regular controls. In this study, the three possible end-points for each patient were as follows:

Survival rate at different times of observation

During the period of 12-57 months after opening the clinic more than 5100 implants were placed and 105 were lost. This study reports in detail however on all those implants, which have been in function for 48 – 47 months [Tables 5, 6, 11]. End-points of observation are shown in Table 10.

In this study, it was found that implants which had been placed in the area of the first molars in the upper and lower jaw show a slightly lower survival rate compared to implants on other locations [Table 12]. All differences found regarding these questions, were not significant however.

Implants: Failures and remedies

Examining 105 losses out of 5100 implant places between 12 and 57 month after the clinic started working, the following pattern of implant loss had been observed: 6 patients had

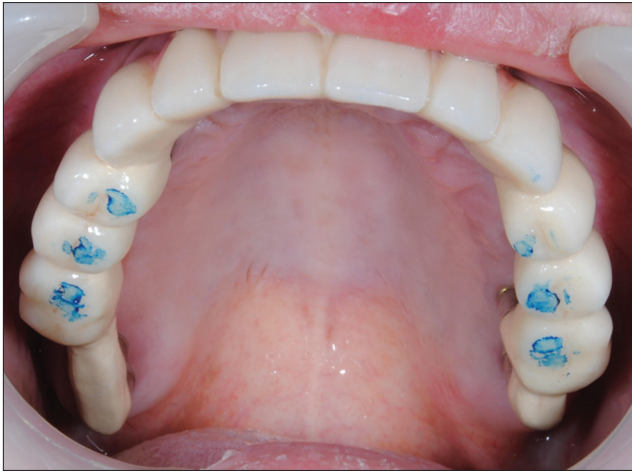

Figure 1: Ideal contact situation after insertion of the metal ceramic bridge in the upper jaw. The concept of “lingualized occlusion” is followed. Second molars are never placed on the bridge; if abutment heads are positioned distally to the first molars, they are prosthetically equipped as (veneered) technical abutments

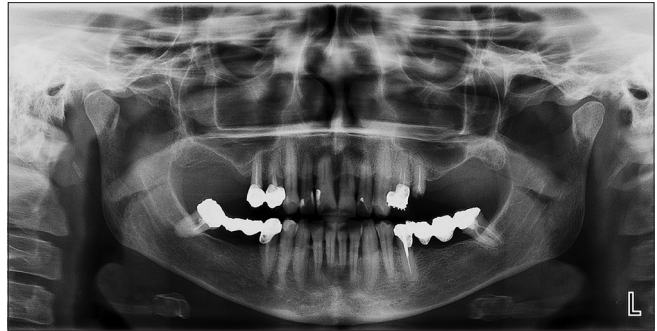

Figure 2: Preoperative panoramic overview before extraction and immediate placement of implants in the upper and lower jaw

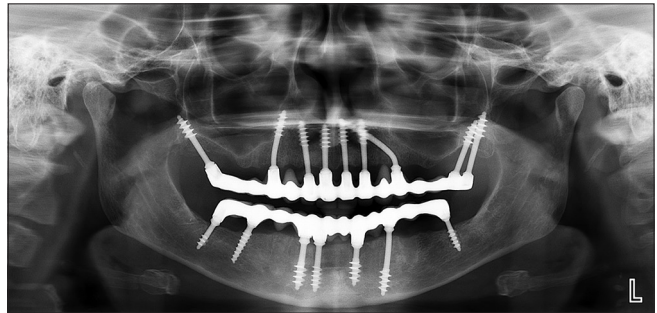


Figure 4: 1.5-year postoperative panoramic picture

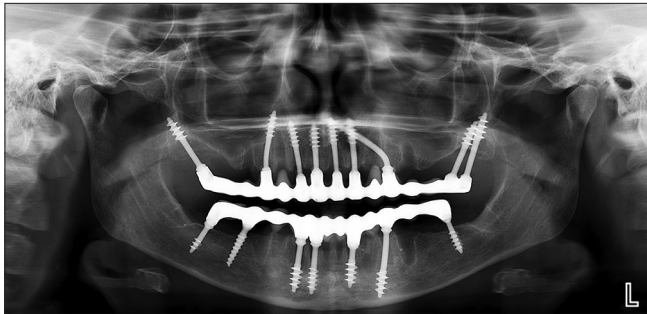


Figure 3: Postoperative panoramic view (after equipping the bridges with Metal fused to ceramic) of the case shown in Figure 2

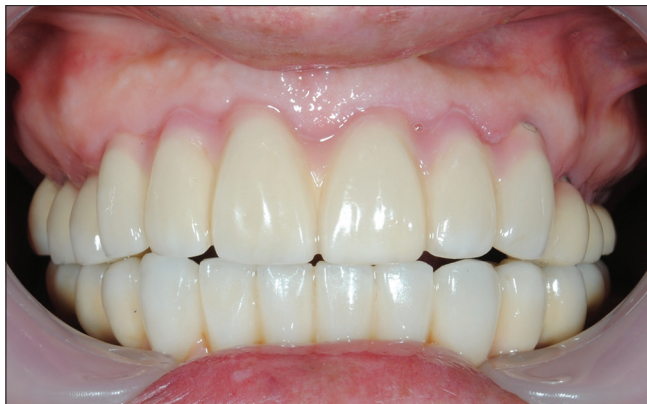

Figure 5: 3-year postoperative clinical picture of the upper and lower Metal fused to ceramic

lost 55 implants, whereas 50 implants were lost in another 38 patients. This indicates that implant losses may be associated to case-specific or patient-related factors, such as (cumulative) overloading of implants due to nonreduced chewing forces,^[12] unilateral or anterior patterns of chewing, unequal mastication

and unexpectedly altered spatial mandibular position after the prosthetic treatment was completed. Table 13 gives an overview on the symptoms as they were reported by patients with complaints.

Influence of the bending of the implant’s necks

To allow nonparallel placement of single-piece implants and to equip them with fixed cemented prosthetic constructions, the necks of these implants must be bent, unless the treatment provider decides to equip the implant heads with angulation adapters. The process of bending not only imposes stresses on the bone structures even up to the point where they might fracture but also influences the mechanical properties of the implant material (and could lead immediately or later to fractures of the implant body). The survival rate for implants whose necks were bent did not differ significantly from the unbent implants in this study.

Technical complications

In the observation period, three decementations, five metal frame fractures, and one case with massive damage of the ceramic veneer on distal surfaces (requiring the fabrication of a new prosthetic workpiece) were observed.

All prosthetic constructions (even if they were planned for short- or medium-term temporary use) were cemented with Fuji Plus (obtained from GC EUROPE N. V, Leuven; Handmix variant; EWT-powder) definitive cement. This procedure is necessary to establish secure and stable splinting between the implants and the bridges as they are required according to the principles of therapy in traumatology and orthopedic surgery (AO Principles).^[13]

Table 5: Implants survival rate and implants characteristics and implant placement

Observed parameters	Radiological follow-up (%)	Clinical inspection as follow-up (%)	Patient report as follow-up (%)
Type of implants			
BECES	94.0	94.1	96.0
KOS	98.4	98.5	98.5
KOS+	50.0	50.0	50.0
BOI	100	100	100
Significance (<i>P</i>)	0.000*	0.000*	0.000*
Preoperative periodontal involvement			
No	90.1	90.8	91.5
In upper jaw	100	100	100
Lower jaw	85.9	86.5	86.9
In both jaws	94.9	95.1	96.9
Significance (<i>P</i>)	0.000*	0.000*	0.000*
Periodontal involvement			
Yes/no	95.4/93.5	95.5/93.6	96.9/95.5
Significance (<i>P</i>)	0.333	0.315	0.322
Jaws			
Maxilla/mandible	92.8/95.8	92.9/95.9	95.8/96.5
Significance (<i>P</i>)	0.975	0.978	0.887
Socket later filled with bone uneventfully			
Yes/no	94.5/93.9	94.6/94.0	96.0/96.1
Significance (<i>P</i>)	0.889	0.909	0.763
Placed in extraction sockets			
Yes/no	94.6/93.9	94.7/93.9	96.1/96.2
Significance (<i>P</i>)	0.972	0.991	0.840
Bent			
Yes/no	97.5/96.1	94.1/94.5	95.6/96.3
Significance (<i>P</i>)	0.413	0.452	0.413

*Statistically significant. The clinically observed survival rate for BECES implants after 48 months was 94.1%; for KOS-implant, it was 98.5%; for KOS Plus, it was 50%; and for BOI, it was 100%. Note, however, that BECES and BOI implants were placed in all bone sites, regardless of the available bone height, and they were placed directly into fresh extraction sockets, trans-sinusally, and in periodontally (often severely) involved cases, whereas KOS/KOS Plus implants could only be placed in healed bone areas, with sufficient vertical bone (10 mm or more) being present. For cases which were planned for treatment with BECES implants, no patient selection was done at all regarding the available amount of bone, its location, general diseases, and periodontal involvement. The survival rates for radiological follow-up, clinical inspection as follow-up, and patient report as follow-up were similar. Slightly better figures in "patient report as follow-up" could indicate that patients without problems are less likely to appear for control appointments.

Table 6: Implant lengths and success for KOS implants

KOS: Implant lengths (mm)	Frequency (percentage of all implants)	Radiological follow-up (%)	Clinical inspection as follow-up (%)	Patient report as follow-up (%)
10	7 (4.9)	85.7	85.7	85.7
12	51 (35.7)	100	100	100
15	83 (58.0)	98.6	98.6	98.6
Significance (<i>P</i>)		0.016*	0.013*	0.012*

In KOS-implants the survival rate depends on the endosseous implant length, with longer lengths leading to up to 100% success rate.

DISCUSSION

In previously published studies on (cortically anchored) lateral basal implants, an immediate function concept for the edentulous mandible was presented with up to 11-year clinical follow-up.^[14] Although the technology of lateral basal implants had proven to be successful even over such a long observation period, the technique never penetrated the market significantly. This is owed to strong opposition of traditional screw implant manufacturers and their protagonists at universities, as well as

to the high demand for surgical skills. Major screw implant manufacturers have constantly supported negative publication against cortically anchored, polished implants, because the success of these designs would question all claims regarding superiority of their specifically designed (expensive) implant surfaces (e.g., SLA, Ti-Unite, etc.) in dental implantology. A group of practitioners has however over decades been working successfully on the concept described in this publication, which had already 20 years ago included an

immediate functional loading protocol. The inclusion of BECES® implants into immediate loading protocols (since

2005), and the development and description of distinct methods of implant placement have led to the unique, powerful, and reliable treatment concept as described it in this article.

A rigid metal frame designed for acrylic or composite veneering was used in all cases. Hence, it could take up to 72 h postoperatively until the bridges were ready for incorporation. The demand for a fixed, rigid splinting of nonparallel implants with multicortical anchorage stems from the field of traumatology. The treatment protocol resembles the procedures in that field, except that here a custom-made splint (bridge) which is inserted as soon as possible postoperatively, whereas in traumatology, the devices to splint the fractures (and the implants) are prefabricated and fixed intraoperatively. In the field of traumatology, “specific implant surface characteristics” (as deemed advantageous by leading dental implant manufacturers and their protagonists at the universities for decades) do not play any role. Bone does neither heal nor integrates implant devices within 72 hrs, nor does it build up mineralization in such a short

Table 7: Pairwise comparison for KOS implant: Implant lengths

	10 mm/KOS, <i>P</i>	12 mm/KOS, <i>P</i>
KOS: Implant length radiological follow-up		
12 mm/KOS	0.013*	
15 mm/KOS	0.030*	0.433
KOS: Implant length clinical inspection as follow-up		
12 mm/KOS	0.010*	
15 mm/KOS	0.029*	0.416
KOS: Implant length patient report as follow-up		
12 mm/KOS	0.008*	
15 mm/KOS	0.029*	0.406

*Statistically significant. *Log rank.

Table 8: Pairwise comparison for BCS implant: Implant lengths

Implant length (mm)/type	Frequency (percentage of all implants)	Radiological follow-up (%)	Clinical inspection as follow-up (%)	Patient report as follow-up (%)
8/BECES	9 (0.9)	66.7	66.7	66.7
10/BECES	23 (2.3)	94.1	95.0	95.0
12/BECES	82 (8.0)	90.0	90.8	91.8
14/BECES	112 (11)	98.0	98.0	98.0
17/BECES	216 (21.2)	91.9	92.1	94.4
20/BECES	318 (31.2)	96.9	96.9	97.7
23/BECES	148 (14.5)	97.5	97.6	99.0
26/BECES	85 (8.3)	90.4	90.4	95.3
29/BECES	26 (2.6)	71.4	71.4	89.5
Significance (<i>P</i>)		0.054	0.060	0.065

Table 9: Implant diameter, type of implants, and implant success

Implant diameter/type	Frequency (% of all implants)	Radiological follow-up (%)	Clinical inspection as follow-up (%)	Patient report as follow-up (%)
3.6/BECES	688 (58.8)	93.5	93.6	95.6
3.5/BECES	14 (1.2)	100	100	100
3.7/KOS	141 (12.1)	98.4	98.5	98.5
3.7/KOS+	4 (0.3)	75.0	75.0	75.0
4.6/BECES	263 (25.8)	98.2	98.3	98.6
5.0/KOS+	2 (0.2)	33.3	33.3	33.3
5.5/BECES	49 (4.2)	66.3	68.0	81.4
16.0/BOI	2 (0.2)	100	100	100
Significance (<i>P</i>)		0.000*	0.000*	0.000*

*Statistically significant.

Table 10: Types of end-points for measuring the success rate for the implants followed in this study

Type of follow-up	Number of implants, <i>n</i> (%)	Duration of follow-up ($X \pm SD$; [median; minimum-maximum])
Radiological follow-up	723 (61.8)	25.76 \pm 11.29 (24; 3-48)
Clinical inspection as follow-up	50 (4.3)	26.36 \pm 10.70 (25; 3-48)
Patient interview as follow-up	397 (33.9)	31.76 \pm 10.21 (36; 3-48)

SD=Standard deviation

Table 11: Implant survival rate for different implant types

Implant type	Follow up period	Number of implants with this follow up	Cumulative number of failure	Cumulative survival rate (%)
BECES/BCS	> 48 months, up to 57 months	1019	31	97.5
KOS	> 48 months, up to 57 months	142	2	98.4
KOS Plus	Up to 27 months	6	3	50
BOI	14 months	2	0	100

Although a total of 5100 implants were placed and observed for 12 – 57 months totally (with 105 implants out of these, having failed), this article reports the detailed results only for 1169 implants which have been observed at least for 48 months

Table 12: Comparison of survival rate for BECES/BCS implants depending on placement in fresh extraction sockets and implant location

Jaws and location	Placed into fresh extraction sockets yes/no	Radiological follow-up	Clinical inspection as follow- up	Patient report as follow- up
Maxilla	307/356 (46.3%/53.7%)	92.8%/91.8%	93.0%/91.9%	95.1%/96.2%
Significance (P)		0.462	0.472	0.267
26, 27, 16, and 17	31/71 (16.3%/83.7%)	86.5%/89.1%	87.1%/89.2%	89.7%/93.0%
Significance		0.346	0.355	0.339
Other	276/285 (49.2%/50.8%)	93.6%/92.4%	93.8%/92.4%	95.8%/97.1%
Significance (P)		0.557	0.577	0.319
Mandible	217/290 (42.8%/57.2%)	97.1%/94.9%	97.1%/95.0%	97.5%/95.8%
Significance (P)		0.340	0.337	0.343

*Statistically significant

Table 13: Symptoms of problems around single implants for all implants which had placed and observed in this study

Symptoms of problems around single implants		n (%)
Mobility	Yes/no	3 (0.3)/1167 (99.7)
Local soft-tissue infection	Yes/no	0 (0)/1170 (100)
Pain	Yes/no	3 (0.3)/1167 (99.7)
Discomfort	Yes/no	2 (0.2)/1168 (99.8)

period. Hence also for dental implants which are designed for immediate loading “specific” implant surface characteristics cannot be of importance for faster integration. Utilizing corticals for real anchorage (and not only for support) is done as part of the concept of the Strategic Implant®. Instead of waiting for “osseointegration,” both the Strategic Implant® as well as the devices in traumatology and orthopedic surgery are immediately “osseofixated” in stable cortical bone, a bone areal that provides almost no metabolism.

In the present study, the mean bone level around the single implant did not change after up to 57 months of functional loading. This observation appears to be in accordance with the previous experience with a similar type of cortically anchored implants; the devices seem not to lead to peri-implantitis, as seen around conventional two-stage implants quite often.

High survival rates have been frequently reported in the literature for immediate function of fixed mandibular complete-arch prostheses supported by three or four implants^[15,16] or on multiple basal implants,^[10] however, when

immediate loading is applied in the maxilla, a larger number of implants is generally used.

The treatment concept uses the load-bearing capacity of the corticals of the maxillary and sphenoid bones in a favorable way. Due to planned tilting, the implant’s thread can be anchored in dense bone structures (especially in the lingual cortical of the distal mandible, the nasal floor, and the pterygoid plate of the sphenoid bone) and well spread anteriorly-posteriorly, giving an effective supporting polygon^[17] marked by four strategic positions. No published clinical studies have investigated immediate loading multiple screwable cortical implants, fixated in the second and third cortical as support for fixed complete arch restorations in the maxilla. This concept of using highly mineralized bone which is far away from the location of the later teeth is best visible on tuberopterygoid implants.

To accomplish immediate functional loading, a metal-ceramic prosthesis was placed within a maximum 3 days after implant placement. The patients were informed preoperatively about the possible provisional nature of these bridges and that the necessity to replace them later for various reasons might arise. All occlusal contacts are placed inside the supporting polygon which is created by the most posterior implants and the canine implants in both the jaws. Since always distal implant are placed, distal cantilevers are not necessary in both jaws. The chewing surfaces are therefore supported by implants from two sides (mesial/distal) in any case. This concept avoids overload osteolysis around single distal implants.

Malo *et al.* shown that their concept of “All-on-4” implant in the upper and lower jaw provide reliable and good results.

The results of this study are well comparable to the results of “All-on-4” treatment modalities.^[18] From mechanical point of view, it is always advisable to avoid cantilevers. The concept of the Strategic Implant® provides the possibility in 100% of the cases and it also allows to provide a full masticatory table from in both the jaws even in cases of an unfavorable jaw relationship. No cases were excluded due to unfavorable jaw relationship (Angle Class II and Class III), although not always a “regular” (Class I) overjet and overbite could be achieved as a result of the prosthetic treatment. Some patients received bilateral or anterior crossbite. Some patients who seemed to have an Angle Class I tooth relationship revealed after extraction their true Angle Class II skeletal jaw relationship: at the end of the treatment and after the joints had repositioned themselves in “joint-centric” position, the occlusal centric was arranged while a true “joint centric” was maintained. This indicates that both forced anterior bites and situations of “long centric” (or better: wrong centric) were treated successfully and that the patients were given their prosthetics in true “joint centric.”

Since all the implants were placed in a private dental center, the average population profited from the treatment. No patient selection was done at all regarding the available bone height, nor for available bone width, nor for any pre-existing diseases or medications. All patients requesting the treatment were consecutively treated. Thus the intent-to-treat-principle was fully respected.

Patients who had received IV-bisphosphonate treatment were excluded from treatment however.

What is more, it must be pointed out, that no patients were rejected from treatment due to “the lack of bone,” nor were “bone augmentations” nor “bone transplants” performed. A number of patients appeared for consultation with uncountable panoramic pictures taken on other centers; they had been refused due to lack of bone and never been offered

treatment. If treatment is done with the technology of the Strategic Implant® bone, augmentations are in general never necessary.

It is therefore a complex task to compare the high success rates reported here with any other technology of conventional “two-stage” implants because the latter are frequently used after bone augmentations or bone transplants. Such procedures carry their own risks and if the augmentation should fail, the implants which were planned for areas under augmentation should logically also be counted as lost, although they have never been placed. Such honest and open statistics for two-stage implants (allowing comparison to this study) does not exist however.

The large number of patients and implants observed during the study period is another advantage of this study. Studies of this size are rare in the field of dental implantology. It had to be accepted that real-life patients skip control appointments and often their compliance is questionable, some of them simply disappear. Many patients consider their former tooth problem as “solved.” They do not wish to turn up for control appointments nor do they accept X-ray diagnosis unless there is a clear demand for this from their side. After 1–2 years, most patients trust that their treatment “works,” many of them, after some years even do not remember that they have received implants and they considered their teeth to be “their own;” patients do not only forget their control appointment, but they also forget that they have implants. This seems to be specific for the intervention with the Strategic Implant® and probably owed to the minimally invasive surgery (in many cases) and to the fact that the bridge is delivered within a maximum of 72 h.

The results of the study are however limited when it comes to determining if age, gender, smoking, and generalized diseases or combinations thereof had influenced the success rate of implants and the cases in general. The problem that was encountered when doing the statistics was that although the total number of implants was very large, the failure and complication rate was extremely low. This did not allow to statistically determine the influence of the mentioned factors. It can be concluded, however, that the traditional contraindications as considered for traditional two-stage implantology do not apply to the Strategic Implant®. Indications and contraindications as a setup for orthopedic surgery and in

Table 14: Survival rate for the bent and nonbent strategic implant (R)

	Radiological follow-up	Clinical inspection as follow-up	Patient report as follow-up
Bent yes/no	97.5%/96.1%	94.1%/94.5%	95.6%/96.3%
Significance (<i>P</i>)	0.413	0.452	0.413

Table 15: Implants survival rate (for each implant type) for placement in fresh extraction sockets or healed bone

Type of implants	Placed into fresh extraction sockets yes/no	Radiological follow-up	Clinical inspection as follow-up	Patient report as follow-up
BECES	493/526 (48.4%/51.6%)	94.7%/93.0%	94.9%/93.0%	96.3%/95.6%
Significance (<i>P</i>)		0.761	0.745	0.867
KOS	29/114 (20.3%/79.7%)	100%/98.0%	100%/98.1%	100%/98.1%
Significance (<i>P</i>)		0.479	0.479	0.483
KOS+	2/4 (33.3%/66.7%)	0%/75.0%	0%/75.0%	0%/75.0%
Significance (<i>P</i>)		0.062	0.062	0.062

*Statistically significant. *Log rank. Survival rates for Implants BCS/BECES, KOS and KOS Plus. The survival of BOI implants is 100%

the trauma field seem to be valid borders Strategic Implant® treatment.^[13]

The results of this study are however limited because not all patients turned up for clinical inspections and had to be interviewed on the phone or through E-mail.

CONCLUSIONS

Within the limits of the study, the following conclusions can be drawn:

1. Immediate functional loading using multiple, cortically anchored screw implants as well as when using compression screw implants, as a support for fixed full arch and segment prosthesis in the upper and lower jaw demonstrated a high implant survival rate (95.7%) after an observation period of up to 57 months. The cumulative survival rate for cortically anchored screw implants was after 4 years 97.5%. The cumulative survival rate for compression screw implants was after 12 months 98.4%, after 2 years 98.4%, after 3 years 98.4%, and after 4 years 98.4%.
2. When tilted posterior implants in the tuberopterygoid region were inserted and the necks of the implants were subsequently bent, it did not affect the high survival rate and caused no clinically relevant bone fractures in that region [Table 14].
3. The chances for the survival of screwable implants anchored in the second or third cortical did not depend on the presence of healed alveolar bone along the vertical shafts of the implants. If these implants are placed into fresh extraction sockets and anchored in the cortical beyond the corticals, they show a high success rate [Table 15].
4. Although a number of implants had to be removed (with some of the prosthetic reconstructions being exchanged), all patients had reached and maintained their clinical treatment aim, with the remaining implants carrying successfully a fixed bridge. The clinical success rate of the immediate functional loading concept with cortically anchored implants (Strategic Implant®) and for implants providing corticalization is 100%.
5. The Strategic Implant® allows the planned and successful transfer of the well-recognized and defined AO-Principles^[10] into the field of dental implantology.
6. Within the observation period of totally 12 - 57 months and when observing 5100 implants placed in this period it can be reported that of signs “Peri-Implantitis” were not found around BECES/BCS implants at all. The Strategic Implant® seems to be resistant to this disease.

The high cumulative implant survival rate for the devices and the technology of the Strategic Implant® indicates (within the limitations of this study) that the immediate functional loading concept with cortically anchored implants or implants providing corticalization of spongy bone for the rehabilitation of completely edentulous mandibles and maxillae

as well as for segments and for single-tooth replacement can be a viable concept even in cases where extractions of teeth were done simultaneously.

Acknowledgments

The author expresses deep gratitude to Dr. Damir Siljanovski for collecting the data and to Prof. Bilijana Milicic (Faculty of Dentistry, Department for Statistics, University of Belgrade/Serbia) for data computing. The works for this article have been supported by the International Implant Foundation, Munich/Germany, www.implantfoundation.org.

Financial support and sponsorship

Nil.

Conflicts of interest

There are no conflicts of interest.

REFERENCES

1. Rocci A, Martignoni M, Gottlow J. Immediate loading in the maxilla using flapless surgery, implants placed in predetermined positions, and prefabricated provisional restorations: A retrospective 3-year clinical study. *Clin Implant Dent Relat Res* 2003;5 Suppl 1:29-36.
2. Olsson M, Urde G, Andersen JB, Sennerby L. Early loading of maxillary fixed cross-arch dental prostheses supported by six or eight oxidized titanium implants: Results after 1 year of loading, case series. *Clin Implant Dent Relat Res* 2003;5 Suppl 1:81-7.
3. Krekmanov L, Kahn M, Rangert B, Lindström H. Tilting of posterior mandibular and maxillary implants for improved prosthesis support. *Int J Oral Maxillofac Implants* 2000;15:405-14.
4. Aparicio C, Perales P, Rangert B. Tilted implants as an alternative to maxillary sinus grafting: A clinical, radiologic, and periotest study. *Clin Implant Dent Relat Res* 2001;3:39-49.
5. Ihde S, Ihde A. Introduction into the Work with Strategic Implants. 3rd ed. Munich, Germany: The International Implant Foundation Publishing; 2017.
6. Goldmann T, Ihde S, Kuzelka J, Himmlova L. Bendable vs. angulated dental implants: Consideration of elastic and plastic material properties based on experimental implant material data and FEA. *Biomed Pap Med Fac Univ Palacky Olomouc Czech Repub* 2008;152:309-16.
7. Available from: <http://falschgutachten.info/analyse-12>. [Last accessed on 2019 Feb 16].
8. Ihde S, Palka L, Gaur V, Ihde A. Critical appraisal regarding the publication “Implant Survival between Endo-Osseous Dental Implants in Immediate Loading, delayed loading, and basal immediate loading dental implants: A 3-year follow-up” as published in *Ann Maxillofac Surg* 2017;7; 237-44, by the authors R. Gharg (Corresponding author), Neha Mishra, Mohan Alexander, Sunil K. Gupta. *Ann Maxillofac Surg* 2018;8:101-7.
9. International Implant Foundation: Consensus on 16 Methods for the Placement of Basal Implants. Available from: <http://www.implantfoundation.org/en/consensus-16-approved-methods-2018-menu-en>. [Last accessed on 2019 Feb 16].
10. Ihde S, Ihde A, Lysenko V, Konstantinovic V, Palka L. New systematic terminology of cortical bone areas for osseo-fixed implants in strategic oral implantology. *J J Anat* 2016;1:7.
11. Ihde S, Ihde A. Cookbook Mastication. 2nd ed. Munich: International Implant Foundation Publishing; 2015.
12. Ihde S. Prophylactic application of botulinum toxin in dental implantology. *Implantodontie* 2005;14:51-5.
13. Ruedi T, Buckley E, Moran CG. *AO Principles of Fracture Management*. Vol. 1. Germany: Thieme; 2007.
14. Ihde S. Outcomes of immediately loaded full arch reconstructions on basal implants and teeth in the mandible: Restrospective report on 115 consecutive cases during a period of up to 134 months. *CMF Implant Dir* 2008;1:50-60.

15. Tarnow DP, Emtiaz S, Classi A. Immediate loading of threaded implants at stage 1 surgery in edentulous arches: Ten consecutive case reports with 1- to 5-year data. *Int J Oral Maxillofac Implants* 1997;12:319-24.
16. Fischer K, Stenberg T. Early loading of ITI implants supporting a maxillary full-arch prosthesis: 1-year data of a prospective, randomized study. *Int J Oral Maxillofac Implants* 2004;19:374-81.
17. Cooper LF, Rahman A, Moriarty J, Chaffee N, Sacco D. Immediate mandibular rehabilitation with endosseous implants: Simultaneous extraction, implant placement, and loading. *Int J Oral Maxillofac Implants* 2002;17:517-25.
18. Ihde S, Ihde A. *Diagnostics and Treatment Plan for the Work with the Strategic Implant®*. 1st ed. Munich: International Implant Foundation Publishing; 2017.