

A Prospective Cohort Study of Maxillary Sinus Complications in Relation to Treatments with Strategic Implants® Penetrating Into the Sinus

Aleksandar Lazarov

Private Dental Surgery, Sofia, Bulgaria

Abstract

Introduction: Rehabilitation with dental implants of total or partial edentulousness in the maxilla encounters a number of difficulties due to the anatomical distinctions and the topography of this region. The maxilla is rigidly attached to the other skull bones, and therefore, its structure is functionally adapted to transmit loads through three main buttresses. Outside these supporting zones, the bone structure is poorly mineralized, or its volume is limited to the thin bone layer. In strategic implantology, a number of defined clinically-proven surgical methods have been proposed to utilize these maxillary load transmitting buttresses. This study was aimed to evaluate its safety with respect to maxillary sinus complications as a result of anchoring Strategic Implants® in the cortical boundaries of the sinus and/or passing through it, to reach the pterygoid plate of the sphenoidal bone. **Materials and Methods:** This prospective cohort study was carried on 217 cortico-basal implants penetrating through the cortical walls of the maxillary sinus (Simpladent GmbH, Gommiswald, Switzerland), placed between September 2013 and December 2014 in a total of 70 patients (131 maxillary sinuses). Two hundred and four implants were anchored in the cortical bone of the sinus protruding into the sinus up to 3 mm, and 13 were placed trans-sinuously. **Results:** None of the implants failed during the observation period, with only one instance of adverse reaction in the maxillary sinus to the polished corticobasal implants. **Discussion:** Anchoring polished corticobasal implants in the wall of the maxillary sinus as well as in the pterygoid plate of the sphenoid bone is a safe and effective procedure that *per se* (if executed properly) does not cause any adverse reaction of the maxillary sinus.

Keywords: Intra-sinusal implant placement, Strategic Implant®, trans-sinusal implant placement

INTRODUCTION

As a result of improved socioeconomic conditions in developed countries, the average life expectancy is steadily growing, which, in turn, increases the number of adult patients with partial or total tooth loss who require dental implants. In addition, in developed countries, conventional dentistry has become extremely expensive, and for this reason, many patients decide on the long-lasting variant of treatment with the Strategic Implant®.^[1] This decision includes an initial investment, but it promises full avoidance (forever) of all problems and costs associated with the teeth.^[2,3]

Rehabilitation with dental implants of total or partial edentulousness in the maxilla encounters a number of difficulties due to the anatomical distinctions and the topography of this region. The maxilla, unlike the mandible, is rigidly attached to the other skull bones, and therefore its

bone structure is functionally adapted to the three main beams: nasomaxillary, zygomaticomaxillary, and tubero-maxillary buttresses. Outside these supporting zones, the bone structure is poorly mineralized, or its volume is limited to the thin bone layer.

According to Wolff's law, skeletal tissues undergo continuous optimization as a response to changes in the functional requirements. In case of the maxillary bone, two morphological developments occur: tooth loss and/or

Address for correspondence: Dr. Aleksandar Lazarov,
Private Dental Practice, Solunska 3, Sofia, Bulgaria.
E-mail: alex.lazarov@yahoo.co.uk

Received: 23-03-2020

Revised: 25-03-2020

Accepted: 30-03-2020

Published: 02-07-2020

This is an open access journal, and articles are distributed under the terms of the Creative Commons Attribution-NonCommercial-ShareAlike 4.0 License, which allows others to remix, tweak, and build upon the work non-commercially, as long as appropriate credit is given and the new creations are licensed under the identical terms.

For reprints contact: WKHLRPMedknow_reprints@wolterskluwer.com

How to cite this article: Lazarov A. A prospective cohort study of maxillary sinus complications in relation to treatments with strategic implants® penetrating into the sinus. *Ann Maxillofac Surg* 2020;10:365-9.

Access this article online

Quick Response Code:



Website:
www.amsjournal.com

DOI:
10.4103/ams.ams_85_20

periodontal disease-related atrophy of the alveolar process in the cranial direction, and the expansion of the maxillary sinus leading to a reduction of the bone in the caudal direction.^[4] The clinical outcome of these two simultaneous developments adds up to pronounced atrophy in this region, i.e., they result in a lack of spongy bone in the area of the distal maxilla, which may impede treatments with conventional two-stage dental implants.

To deal with this problem, dental clinicians have developed a number of clinical protocols, such as sinus lifts,^[5,6] All-on-4,^[7] All-on-6,^[8] or classic two-piece zygoma implants,^[9,10] which have a number of disadvantages such as increased treatment time, morbidity and cost of the procedure. In the past 15 years, the technology of Strategic Implant[®] has been developing and optimizing to address disadvantages and shortages of conventional treatment options.

The technology of Strategic Implant[®] is based on 16 defined clinically-proven surgical methods. Namely, methods 8a, 8b, 10a, 10b, and 11a are applied in the regions of the maxillary sinus to utilize these load transmitting buttresses.^[11]

This study was aimed to evaluate the safety of anchoring polished cortico-basal implants in these areas, which among others include mesial and distal cortical of the maxillary sinus (Method 8a, 8b), fusion area between maxilla and pterygoid process of the sphenoidal bone (Method 10a, 10b), bone on the palatal side of the sinus (Method 11a).^[11]

At many dental universities, students are taught to be afraid of/or avoid, sinus involvement. “It is enough to get briefly acquainted with the English language literature to render this notion as unjustified and wrong. As early as the 1970s and 1980s, studies were conducted on the maxillary sinus response to intra- and trans-sinus dental implants. The results are unanimous-the sinus either does not react at all to intrasinusly placed implant or responds with nonpathological mucosal hypertrophy and lack of any clinical or radiological features of chronic or acute maxillary sinusitis.^[12-18] All these studies were performed with conventional 2-stage implants with rough (sand-blasted and or acid etched endosseous surface), and we expect that the response of the soft tissues in the maxillary sinus to polished implants is even more benign. The same was observed for screws and plates in maxillo-facial surgery, which also are polished and come into contact with the maxillary sinuses.

MATERIALS AND METHODS

Between June 2013 and December 2014, 217 strategic implants, penetrating through the maxillary sinus cortical into the sinus cavity, were placed in our clinic. Two hundred and four implants were penetrating through the sinus cortical into the maxillary sinus up to 4 mm and 13 were placed trans-sinus, going through the sinus floor and the lateral wall of the sinus to achieve anchorage in the pterygoid process of the sphenoid bone or in

palatal process of maxillary bone [Figure 1] in a total of 70 patients (131 maxillary sinuses).

The number of implants per sinus was between 1 and 3, on average 1.65.

Figure 1 shows the distal implants were placed in a trans-sinus way (implants penetrate entirely through the sinus cavity). The implant in the area of 23 was placed in an intra-sinus way (the implant is partially penetrating the sinus cavity by 1–4 mm). The sinuses responded with minor mucosal hypertrophy.

Between June and December 2019, the same cohort of patients was approached for clinical and radiological assessment. Due to a long follow-up, not all patients were available for examination in the clinic. As a result, three subgroups were created: Group A included 19 out of 70 patients who were clinically examined during check-up appointments at which panoramic radiographs were taken with a mean follow up of 64 months; Group B with 29 patients who could not come for the clinical examination during that period and were interviewed on the telephone and asked questions included in the questionnaire based on sinus pathology [Figure 2]; Group C included the remaining 22 patients who could not have been reached-for this group available control OPGs were examined with mean radiological follow-up of 23 months [Table 1]. In addition, in Group B, previous control OPGs were analyzed with mean radiological follow-up of 46 months. Two patients with a history of maxillary sinusitis before implant treatment were excluded from the analysis.

One hundred and fifty-one of these implants placed in 90 sinuses Group A and B were followed for approximately 5.5 years with the mean value of 66 months. The reaction of the maxillary sinuses to the polished implants was examined radiographically utilizing panoramic X-ray (OPG), and clinically for the presence of symptoms of maxillary sinusitis.

Sixty-three of the implants placed in 41 sinuses from the Group C of the patients who were not reachable (4 died, the rest changed contact details), were examined based on available control OPGs with mean radiological follow-up of 23.5 months.

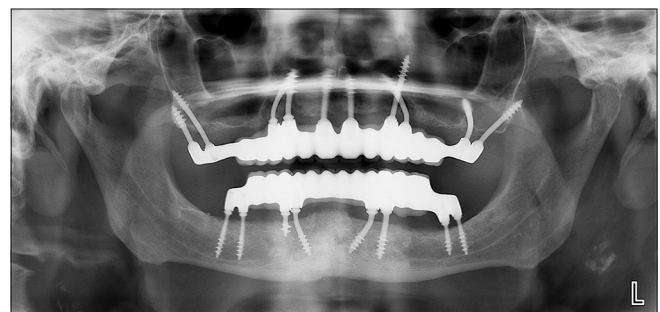
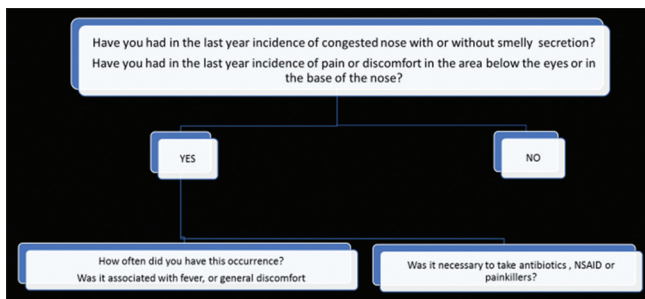


Figure 1: The distal implants were placed in a trans-sinus way (implants penetrate entirely through the sinus cavity). The implant in the area of 23 was placed in an intra-sinus way (the implant is partially penetrating the sinus cavity by 1–4 mm). The sinuses responded with minor mucosal hypertrophy

Table 1: Patient groups according to follow-up

Group	Number of patients	Implants	Sinuses with implants inside	Control status	Symptomatic maxillary sinus
Group A: Patients controlled for 5-6.5 years and controlled clinically after this period	19	61	36	66 months mean, clinical and radiological control	1
Group B: Patients which gave interviews after 5.5-6 years	29	90	54	Last radiologic control: 46 months after implant insertion	0
Group C: Patients lost to follow up after 23.5 months (incl. 4 died)	22	66	44	Last radiologic control: 23 months after implant insertion	Unknown
Total	70	217	131		

**Figure 2:** Maxillary sinus pathology oriented questionnaire

RESULTS

Preoperative status

Ninety-eight of the maxillary sinuses showed no visible changes of soft tissues on the preoperative panoramic picture; in the case of 33 sinuses, preoperative lesions (mucosal hypertrophy, mucocele) were present/visible before insertion of the implants but without clinical symptoms of maxillary sinusitis [Figure 3].

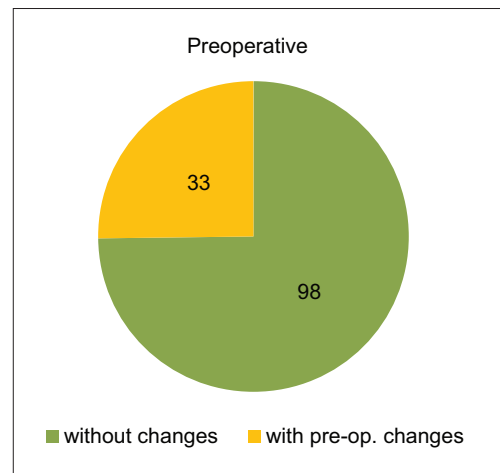
Postoperative results

Between 5 and 6 years after treatment, a radiographic assessment, clinical examination, or telephone interview of the sinus condition was performed again in 48 patients-Groups A and B, which accounted for 151 implants placed in 90 sinuses. Furthermore, the patients were specifically inspected for maxillary sinus infections.

Twenty-two patients-Group C (66 implants placed in 41 sinuses) who could not have been reached at the time of the analysis only available control OPGs were inspected, with a mean follow-up of 23 months.

In the sinus group without preoperative alterations in 11 cases, slight to moderate hypertrophy of the maxillary mucosa was observed on the panoramic radiographs. In the group with preoperative mucosal alterations, there was no increase in hypertrophy; even in some sinuses, there was a visible reversal of the pathological process. In one single maxillary sinus 4 years postoperatively, we detected both clinical and radiological signs of active maxillary sinusitis [Table 2].

Of 98 sinuses which did not present preoperative thickening of the Schneiderian membrane, 11 cases showed such thickening

**Figure 3:** Green: Normal/healthy preoperative status of the sinus in the panoramic radiograph. Yellow: Visible mucosal hypertrophy, mucocele, etc., on the preoperative panoramic radiograph

after the treatment, but without signs of infection of the maxillary sinuses. In the group with preoperative thickening of the Schneiderian membrane, one maxillary sinus developed active sinusitis detected at the control visit after 4 years. A close examination of this case revealed that possible reason could be that the crown margin on the most distal implants had been too far subgingivally. Such a location had caused a chronic local infection that ascended into the maxillary sinus. Nevertheless, the patient refused to undergo any of the offered treatments.

DISCUSSION

The results of our retrospective study confirm the results of numerous studies done over the past 40 years, namely that polished implants placed intra-sinus, trans-sinus, or even into the nasal cavity do not cause any adverse mucous membrane reaction and the situation remains stable years after implantation.^[18-20]

Another important conclusion is that implants placed in sinuses with preoperative alterations (hypertrophy of sinus membrane, polyps, and mucoceles) do not cause exacerbation and worsening of the clinical picture. Moreover, in several cases, an improvement in the status of the sinus has been observed, which most probably is due to intra-operative removal of the odontogenic reason for sinus pathology.

Table 2: An overview of the sinusal conditions preoperatively and 2-6 years postoperatively, including all groups

	Preoperative	2-6 years postoperative	Treatment for problems in the maxillary sinus
Sinuses without a detectable thickening of the mucosa, mucocele, etc.	98	11 sinuses with development of thickening of mucosa (Scheiderian membrane), but no clinical symptoms of sinusitis 87 sinuses with no changes	No treatment
Sinuses with a detectable thickening of the mucosa, mucocele, etc.	33	7 sinuses showed remission of intra-sinus thickening of the mucosa and no active infection	No treatment
Sinuses with an active sinusitis	0	1 sinus showed recurrent (2× per year) infection of one maxillary sinus	The patient requested no treatment, not even antibiotics during exacerbations

In one case only, the development of one-sided sinusitis was observed as a result of chronic irritation caused by the dental bridge edge and deteriorated hygiene [Figure 4].

To overcome the exacerbation of the infection (one or two times per year), the following treatment options were offered to the patient:

- To perform an endoscopic revision of semilunar hiatus, disinfecting lavage of the sinus (e.g., through a FESS intervention)
- To resolve the cause of the problem at the upper left distal implant by moving the connection area between the head of the implant and the crown into a self-cleaning zone and/or
- To perform nasal irrigation by use Neti Pot^[21,22] in combination with antibiotics in case of exacerbation, corticosteroids and/or nonsteroidal anti-inflammatory drug
- To do nothing.

The patient decided for the last option: To live with about two exacerbations of the (probably) chronic sinusitis in his left maxillary sinus without undergoing any treatment. His decision was similar to the decision taken by many patients who have maxillary sinusitis without any dental implants.

One limitation of this study is that radiological findings are based on OPGs only. CT examinations pre and postoperatively would have been more revealing of pre- real intra-sinus responses. Still, this examination is not a part of a standard treatment protocol. Other limitation of the study is the fact that a relatively large number of patients (about 30%) dropped off. However, a considerably big group of patients (48), i.e., implants (151) and sinuses (90), were followed for an extended period (66 months). It has to be taken into account that this study was done in a private implant clinic and that the number of patients available for clinical control after such a long period is relatively low. That's a weak (but unproblematic) point of this study but does not diminish the value of the research itself as it was done in a real-life environment and not at University. Furthermore, it should be mentioned that in general, the tendency of patients treated with the technology of Strategic Implant[®] to come for control after more than 2 years is quite low because no regular maintenance is required. Patients tend to forget that they have implants after the first and/or

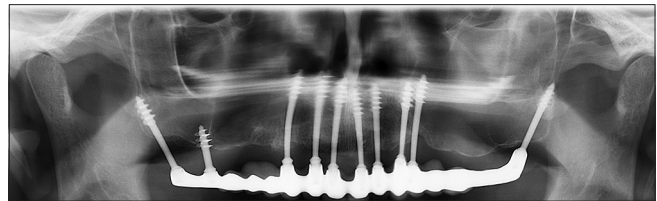


Figure 4: Shadowing in the left sinus has been observed, together with clinical symptoms of maxillary sinusitis. Treatment of the condition did not require the explanting of implants because polished implants were not the cause of the problem

second control. Nevertheless, patients tend to come instead to the initial treatment provider for a check-up if they have a problem in later years.

CONCLUSION

Cortically anchored, polished cortico-basal implants are a safe treatment option in cases of advanced atrophy of the maxilla. Anchoring such implants in the cortical floor of the maxillary sinus as well as in the pterygoid plate of the sphenoid bone is a safe and effective procedure which *per se* (if executed properly) does not cause an infection of the maxillary sinus. Hence, this treatment is a very viable alternative to older conventional treatment protocols with dental implants and “sinus lifts” in cases of (advanced) atrophy of the maxilla.

Financial support and sponsorship

Nil.

Conflicts of interest

There are no conflicts of interest.

REFERENCES

1. Lazarov A. Immediate functional loading: Results for the concept of the strategic implant[®]. *Ann Maxillofac Surg* 2019;9:78-88.
2. Ihde S, Sipic O. Dental implant treatment and immediate functional loading (1). Case Report and Considerations: Extended Treatment Options Using the Strategic Implant[®] and Indications and Objectives for Comprehensive Dental Implant Treatment. *Ann Maxillofac Surg* 2019;9:465-9.
3. Ihde S, Sipic O. Functional and Esthetic Indication for Dental Implant Treatment and Immediate Loading (2) Case Report and Considerations: Typical Attitudes of Dentists (and their Unions) toward Tooth Extractions and the Prevention of Early, Effective, and Helpful Dental Implant

- Treatment in the European Union. *Ann Maxillofac Surg* 2019;9:470-4.
4. Wolff J. *The Law of Bone Remodeling*. Trans. By P. Maquet and R. Furlong. Berlin: Springer Verlag; 1896.
 5. Stern A, Green J. Sinus lift procedures: An overview of current techniques. *Dent Clin North Am* 2012;56:219-33, x.
 6. Zhou X, Hu XL, Li JH, Lin Y. Minimally invasive crestal sinus lift technique and simultaneous implant placement. *Chin J Dent Res* 2017;20:211-8.
 7. Malo P, de Araújo Nobre M, Lopes A, Moss SM, Molina GJ. A longitudinal study of the survival of All-on-4 implants in the mandible with up to 10 years of follow-up. *J Am Dent Assoc* 2011;142:310-20.
 8. Cucchi A, Vignudelli E, Franco S, Ghensi P, Malchiodi L, Corinaldesi G. Evaluation of crestal bone loss around straight and tilted implants in patients rehabilitated by immediate-loaded full-arch all-on-4 or All-on-6: A prospective study. *J Oral Implantol* 2019;45:434-43.
 9. Chrcanovic BR, Albrektsson T, Wennerberg A. Survival and complications of zygomatic implants: An updated systematic review. *J Oral Maxillofac Surg* 2016;74:1949-64.
 10. Tuminelli FJ, Walter LR, Neugarten J, Bedrossian E. Immediate loading of zygomatic implants: A systematic review of implant survival, prosthesis survival and potential complications. *Eur J Oral Implantol* 2017;10 Suppl 1:79-87.
 11. Ihde S. Indications and treatment modalities with corticobasal jaw implants. *Ann Maxillofac Surg* 2019;9:379-86.
 12. Zhong W, Chen B, Liang X, Ma G. Experimental study on penetration of dental implants into the maxillary sinus in different depths. *J Appl Oral Sci* 2013;21:560-6.
 13. Brånemark PI, Adell R, Albrektsson T, Lekholm U, Lindström J, Rockler B. An experimental and clinical study of osseointegrated implants penetrating the nasal cavity and maxillary sinus. *J Oral Maxillofac Surg* 1984;42:497-505.
 14. Jung JH, Choi BH, Zhu SJ, Lee SH, Huh JY, You TM, *et al*. The effects of exposing dental implants to the maxillary sinus cavity on sinus complications. *Oral Surg Oral Med Oral Pathol Oral Radiol Endod* 2006;102:602-5.
 15. Tabrizi R, Amid R, Taha Özkan B, Khorshidi H, Langner NJ. Effects of exposing dental implant to the maxillary sinus cavity. *J Craniofac Surg* 2012;23:767-9.
 16. Jung JH, Choi BH, Jeong SM, Li J, Lee SH, Lee HJ. A retrospective study of the effects on sinus complications of exposing dental implants to the maxillary sinus cavity. *Oral Surg Oral Med Oral Pathol Oral Radiol Endod* 2007;103:623-5.
 17. Ragucci GM, Elnayef B, Suárez-López Del Amo F, Wang HL, Hernández-Alfaro F, Gargallo-Albiol J. Influence of exposing dental implants into the sinus cavity on survival and complications rate: A systematic review. *Int J Implant Dent*. 2019;5:6.
 18. Khairnar M, Gaur V. Evidence of bone formation in the nasal floor around polished surface bi-cortical screw implants after indirect nasal lift in an atrophied maxilla: Cone beam computed tomography-based case report. *J Indian Soc Periodontol*. 2015;19:236-8.
 19. Pałka LR, Lazarov A. Immediately loaded bicortical implants inserted in fresh extraction and healed sites in patients with and without a history of periodontal disease. *Ann Maxillofac Surg*. 2019;9:371-8.
 20. Ihde S, Pałka Ł, Janeczek M, Kosior P, Kiryk J, Dobrzyński M. Bite reconstruction in the aesthetic zone using one-piece bicortical screw implants. *Case Rep Dent* 2018;2018:4671482.
 21. Rabago D, Zgierska A. Saline nasal irrigation for upper respiratory conditions. *Am Fam Physician* 2009;80:1117-9.
 22. Keller S, König V, Mösges R. Thermal water applications in the treatment of upper respiratory tract diseases: A systematic review and meta-analysis. *J Allergy (Cairo)* 2014;2014:943824.