




Cranio-maxillofacial
Implant Directions®

Vol.15 N° 3

June 2021

English Edition



CASE REPORT:
DENTAL IMPLANTS IN EXTRACTION SOCKETS AND PERIODONTALLY
INVOLVED BONE AREAS: THE TECHNOLOGY OF THE STRATEGIC IMPLANT®
RADICALLY CHANGES TREATMENT POSSIBILITIES
O. SIPIC, S. IHDE

ISSN 1864-1199 / e-ISSN 1864-1237

OFFPRINT



Editorial board

Managing editor

Dr. Łukasz Pałka
regmed.klinika@gmail.com

Dr. Vivek Gaur
drvivekgaur@yahoo.co.in

Coordinating editor

Joanna Dołbaczuk
j.dolbaczuk@gmail.com

Editorial board (in alphabetic order)

Dr. Muhammad Alobayat, Palestine
Dr. Pablo Diaz, Ecuador
Dr. Anita Doshi, India
Dr. Marcos Daniel Gonzales, Colombia
Dr. Georg Huber, Germany
Prof. Dr. Vitomir S. Konstantinovic, Serbia
Dr. Alexander Lazarov, Bulgaria
Dr. Igor Lell, Germany
Dr. Valeri Lysenko, Ukraine
Dr. Werner Mander, Spain
Dr. Juri Mitrushenkov, Russia
Dr. Mahendra Perumal, India
Dr. Andrii Shmojlov, Russia
Prof. Dr. Jan Vares, Ukraine

Evidence reports and Critical Appraisals

IF Research & Evidence Dept.

Annual Subscription

Euro 2.800

Copyright

Copyright ©2006 - 2021 by
International Implant Foundation
DE- 80802 Munich / Germany
www.implantfoundation.org

Contact

publishing@implantfoundation.org

CMF.Impl.dir.

ISSN 1864-1199
e-ISSN 1864-1237

Disclaimer

Hazards

Great care has been taken to maintain the accuracy of the information contained in this publication. However, the publisher and/or the distributor and/or the editors and/or the authors cannot be held responsible for errors or any consequences arising from the use of the information contained in this publication. The statements or opinions contained in editorials and articles in this publication are solely those of the authors thereof and not of the publisher, and/or the distributor, and/or the IIF.

The products, procedures and therapies described in this work are hazardous and are therefore only to be applied by certified and trained medical professionals in environment specially designed for such procedures. No suggested test or procedure should be carried out unless, in the user's professional judgment, its risk is justified. Whoever applies products, procedures and therapies shown or described in this publication will do this at their own risk. Because of rapid advances in the medical science, IF recommends that independent verification of diagnosis, therapies, drugs, dosages and operation methods should be made before any action is taken.

Although all advertising material which may be inserted into the work is expected to conform to ethical (medical) standards, inclusion in this publication does not constitute a guarantee or endorsement by the publisher regarding quality or value of such product or of the claims made of it by its manufacturer.

Legal restrictions

This work was produced by IF Publishing, Munich, Germany. All rights reserved by IF Publishing. This publication including all parts thereof, is legally protected by copyright. Any use, exploitation or commercialization outside the narrow limits set forth by copyright legislation and the restrictions on use laid out below, without the publisher's consent, is illegal and liable to prosecution. This applies in particular to photostat reproduction, copying, scanning or duplication of any kind, translation, preparation of microfilms, electronic data processing, and storage such as making this publication available on Intranet or Internet.

Some of the products, names, instruments, treatments, logos, designs, etc. referred to in this publication are also protected by patents and trademarks or by other intellectual property protection laws (eg. «IF», «IIF» and the IF-Logo) are registered trademarks even though specific reference to this fact is not always made in the text.

Therefore, the appearance of a name, instrument, etc. without designation as proprietary is not to be construed as a representation by publisher that it is in the public domain.

Institutions' subscriptions allow to reproduce tables of content or prepare lists of Articles including abstracts for internal circulation within the institutions concerned. Permission of the publisher is required for all other derivative works, including compilations and translations. Permission of the publisher is required to store or use electronically any material contained in this journal, including any article or part of an article. For inquiries contact the publisher at the address indicated.



Dental implants in extraction sockets and periodontally involved bone areas: The Technology of the Strategic Implant[®] radically changes treatment possibilities

Authors

Prof. Olga Sipic^{1,2}

Prof. Dr. Stefan Ihde^{1,2}

Key Words

Immediate functional loading, Strategic Implant[®], sinus-lift, periodontally involved soft tissues, bone healing

How to cite this article

Sipic O., Ihde S.

Dental implants in extraction sockets and periodontally involved bone areas: The Technology of the Strategic Implant[®] radically changes treatment possibilities
CMF Impl Dir 2021; 15: 190 - 201

¹ Evidence and Research Department, International Implant Foundation, Leopoldstr. 116, 80802 München, Germany; olja.sipic@gmail.com

² Prosthetic Dept. Jaipur Dental College, Maharaj Vinayak Global University, Jaipur, Rajasthan, India

Abstract

If the Technology of the Strategic Implant® is applied, bone augmentations and healing times are not part of the treatment plan for implants any more. As this article shows, bone augmentations, sinus lifts, waiting time are not necessary for dental implant treatment and delivering fixed teeth as long as cortically anchored implant designs with polished endosseous surfaces are used. Periodontally involved soft tissues are not an obstacle in immediate implant treatment with Strategic Implant®.

Introduction

In the field of conventional dental implantology, the treatment of periodontal infections must be done before conventional dental implants can be placed. This leads to the paradox situation that either periodontal treatment must be done before implant placement, or all teeth must be removed considerably earlier before implant placement and an intermediate prosthesis is then delivered. This prolongs the overall treatment time and increases the costs. Both circumstances reduce the chance that the patient will opt for implants.

Recent studies have shown that the Technology of the Strategic Implant® not only does not lead to "periimplantitis", but is also allows a fast approach in periodontally involved cases^{1,2}: Teeth and periodontally involved parts of the gums are removed immediately before implants are placed, and subsequently an immediate load-

ing protocol is carried through.

In this article we would like to show the possibilities of the Technology of the Strategic Implant® and the differences between conventional dental implant on three clinical cases.

Case Studies

Case 1

A 54 year old male patient, smoker, requested an overall treatment of his jaw condition. The treatment provider recommended the removal of all teeth due to their periodontal involvement, mobilities, recurrent infections and reduced lifespan, Fig.1. We informed the patient also that repairs on various single teeth will not improve the masticatory possibilities at all.

At the same appointment when all teeth were extracted, all implants were placed (ten cortically anchored implants in the upper jaw and eight cortically anchored implants in the lower jaw). Uneventful healing is seen on the panoramic picture which was taken during 3-month-control, as well as during 7-years-control, Fig. 2 and 3.

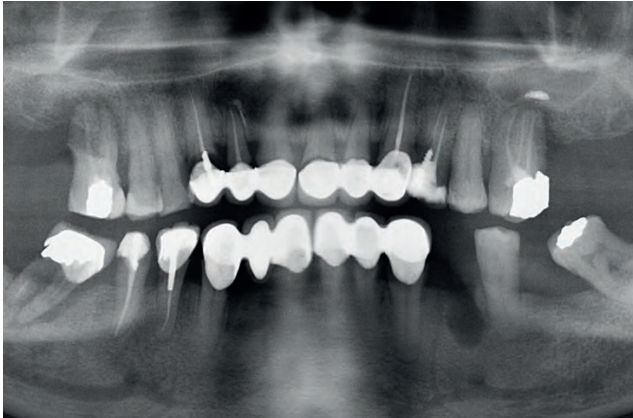

Fig. 1 Pre-operative panoramic picture showing generalized periodontal disease and bone loss at all teeth and deep endo-perio lesions at a number of teeth.

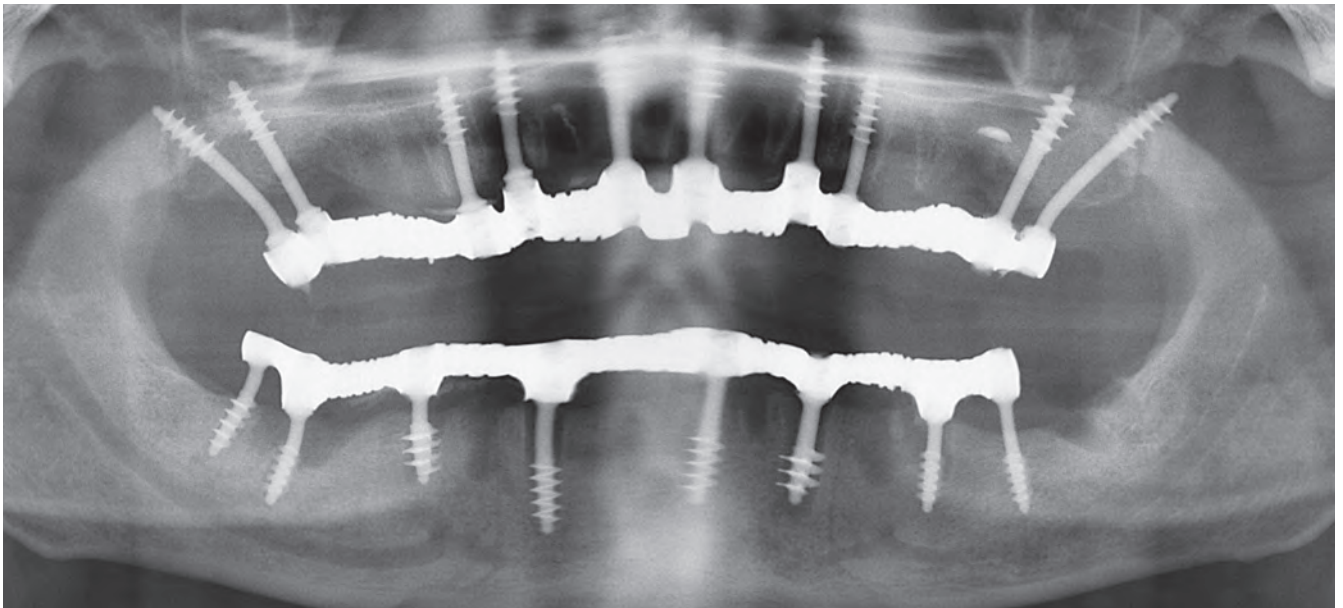


Fig. 2 The 3-month post-operative panoramic picture shows that all teeth were extracted and some of the implants were placed in the extraction sockets (e.g. in area 47, 25, u.a.) and others in healed bone areas.

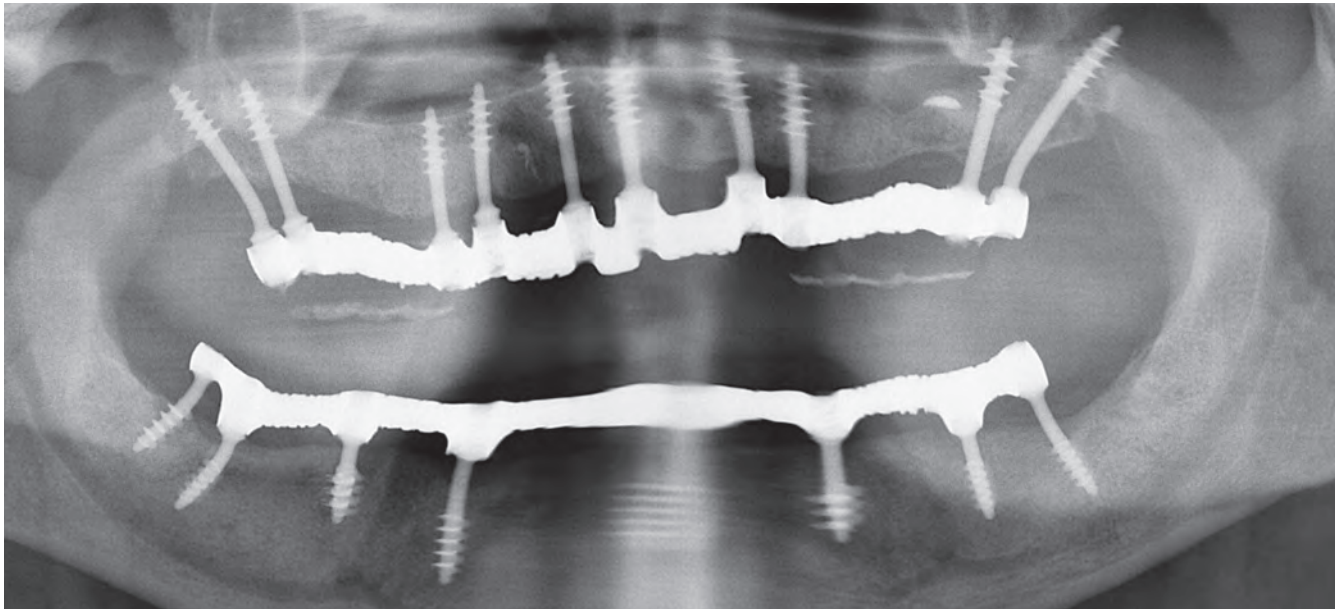


Fig. 3 The 7-year post-operative panoramic picture shows uneventful healing, absence of infections, formation of a continuous bone line, no crater-like bone-loss, and that all pre-existing bone craters have re-filled independently from the implant placement. The implant 47 which was placed deep into a periodontally involved site (into the 2nd cortical^{III}) is now surrounded by healthy bone.

Case 2

A 53 year old male patient, smoker requested the restauration of both jaws with bridges on implants in an immediate loading procedure. The pre-operative picture (Fig. 4) revealed deep pockets, elongations and generalized bone loss. All teeth were extracted and replaced by implants, using the technology of the Strategic Implant®, Fig. 5.

Three months later during the 2nd clinical and radiological control the bone sites appeared to heal uneventfully (Figs. 6 and 7). For better visibility the figures show only details on the areas described here.

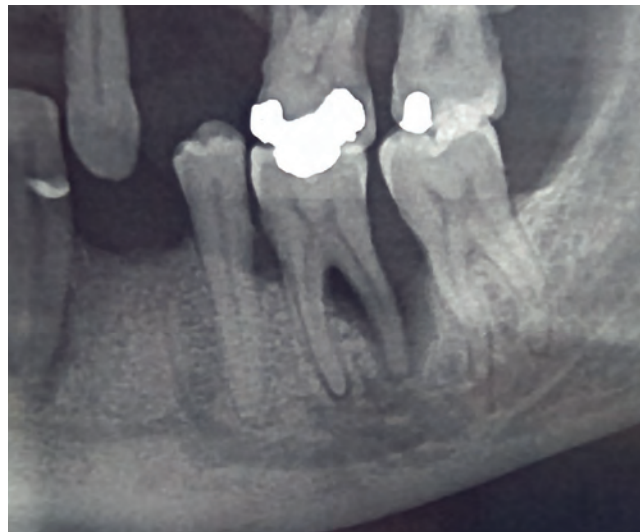

Fig. 4 Section of the pre-operative panoramic pictures showing left lower jaw of the patient. 34 and 36 is missing, 35 had moved distally. 37 shows profound periodontal involvement on the distal root. 33 shows a large translucency in the area of the root, resembling a peri-apical infection.

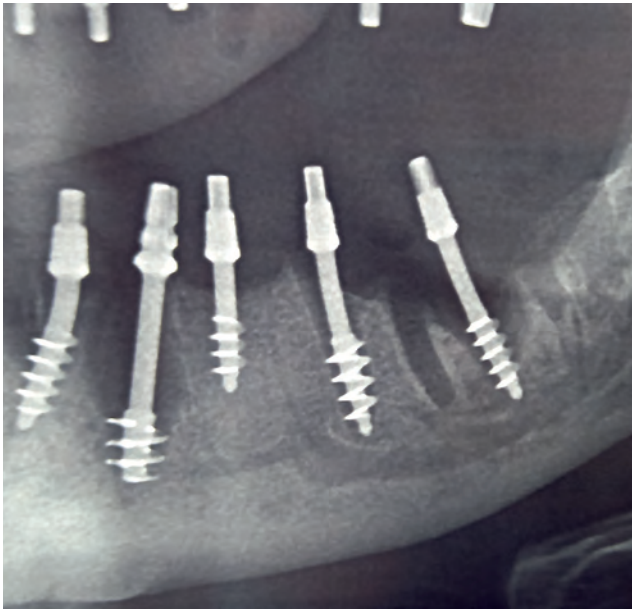


Fig. 5 Postoperative section of the panoramic picture, showing the lower left mandible. One Strategic Implant[®] has been placed into the deepest section of the periodontal defect of the distal root of tooth 37. No implant was placed in area 38. A wide diameter implant (BCS 4.6 23) had been placed partly apically to the peri-apical infection of tooth 33.




Fig. 6 During the 3-month control this picture was taken:
All defects in the bone heal unevenly and have started to mineralize.

Case 3

The patient shown in case 3 was 60 years old and he had profound periodontal involvement, partially with pockets reaching to the apex of the teeth. All teeth incl. a retented tooth 48 were removed and in the same treatment implants in the upper and lower for circular bridges were placed.

Two years later the implant sited appeared uneventfully and new bone had grown vertically upwards along the implants.

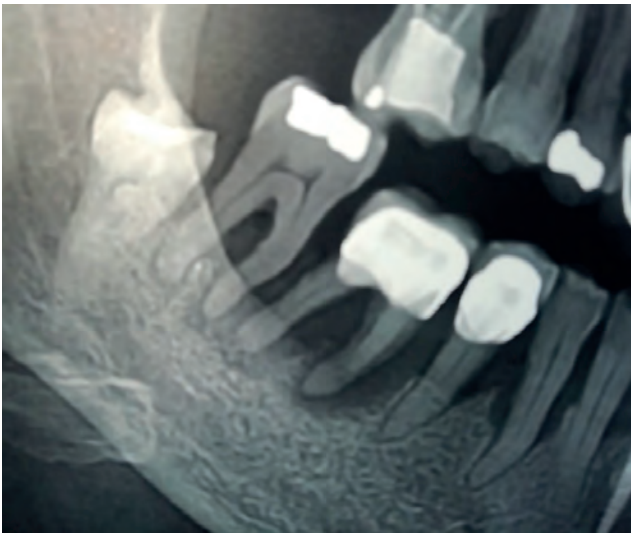


Fig. 7 Panoramic view on the lower right segment of the mandible with a retented tooth 48, and teeth 47, 46, 45 with profound periodontal involvement. Also tooth 44 is showing advanced bone loss.

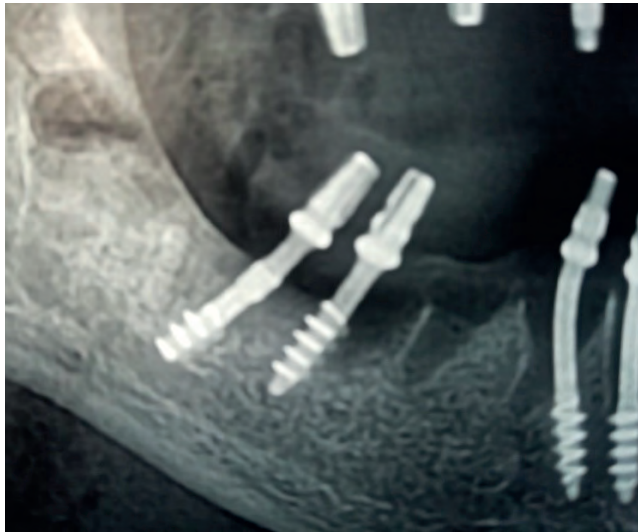

Fig. 8 Three months postoperatively it is visible, that all extraction sockets are undergoing a healthy healing process, and that their bony content shows signs of mineralization.

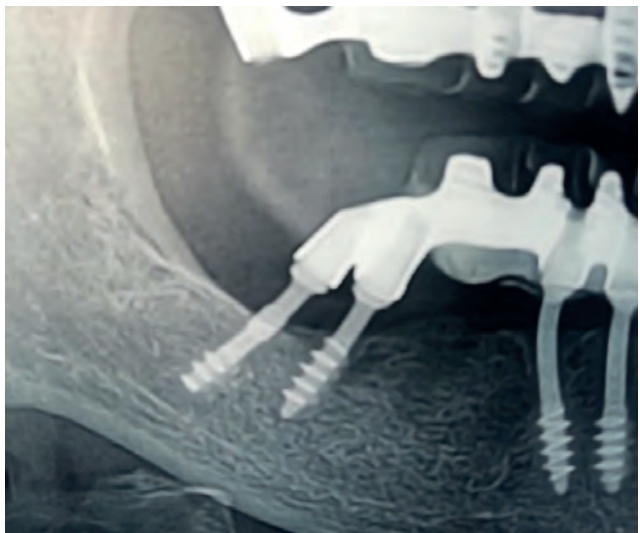


Fig. 9 After two years a new crestal bone line in the lower left mandible has developed and the former extraction sockets and pockets have almost levelled out.

Case 4

A 43 year old male patient, heavy smoker, was treated in the upper and lower jaw with the Strategic Implant® technology. In area 37 the periodontally involved tooth 37 was removed right before implant placement. The heavy periodontal involvement around this tooth had left almost no bone in that region. Nevertheless placement of an implant was in this region necessary, due to the fact that the area of the 2nd lower molar is a strategic position which must be equipped. Due to the low primary stability the implant was removed right after taking the (immediate post-operative) impression, and it was placed back only a few minutes before cementation. Fig. 10 shows the postoperative control radiograph (implant 37 has been removed after impression taking and it is therefore not on the picture), Fig. 11 shows the 8-month control. Area 37 is under uneventful healing.

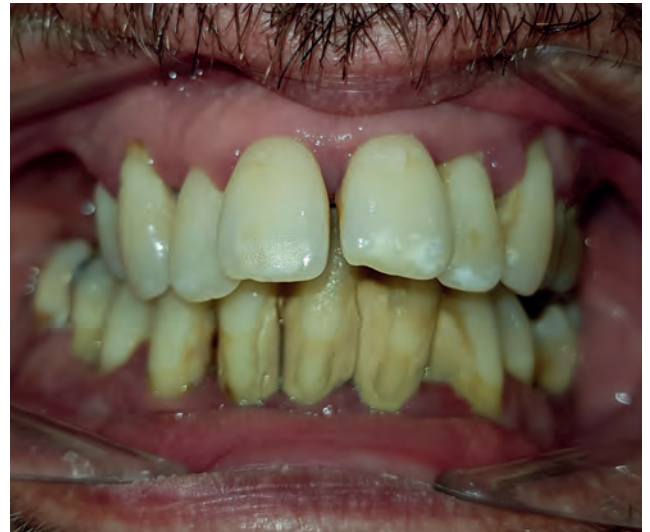

Fig. 10 Preoperative clinical view of the Case 4 patient. Profound periodontal involvement in the distal zones. Massive accumulation of tartar in both jaws.

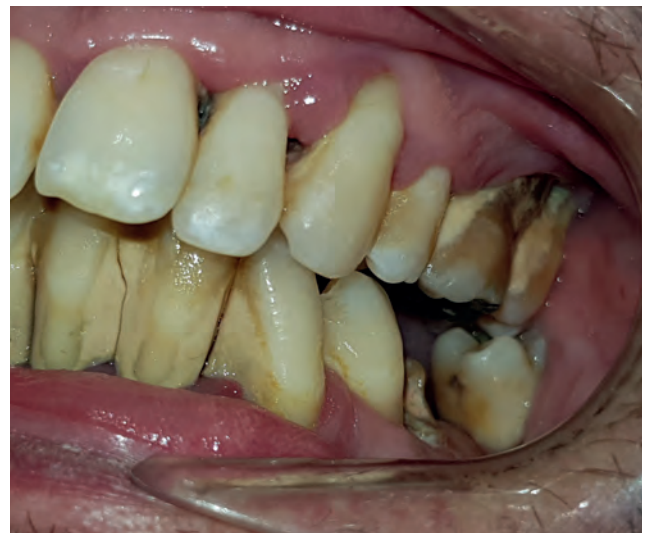

Fig. 11 shows severe periodontal involvement in the distal part of both jaws.

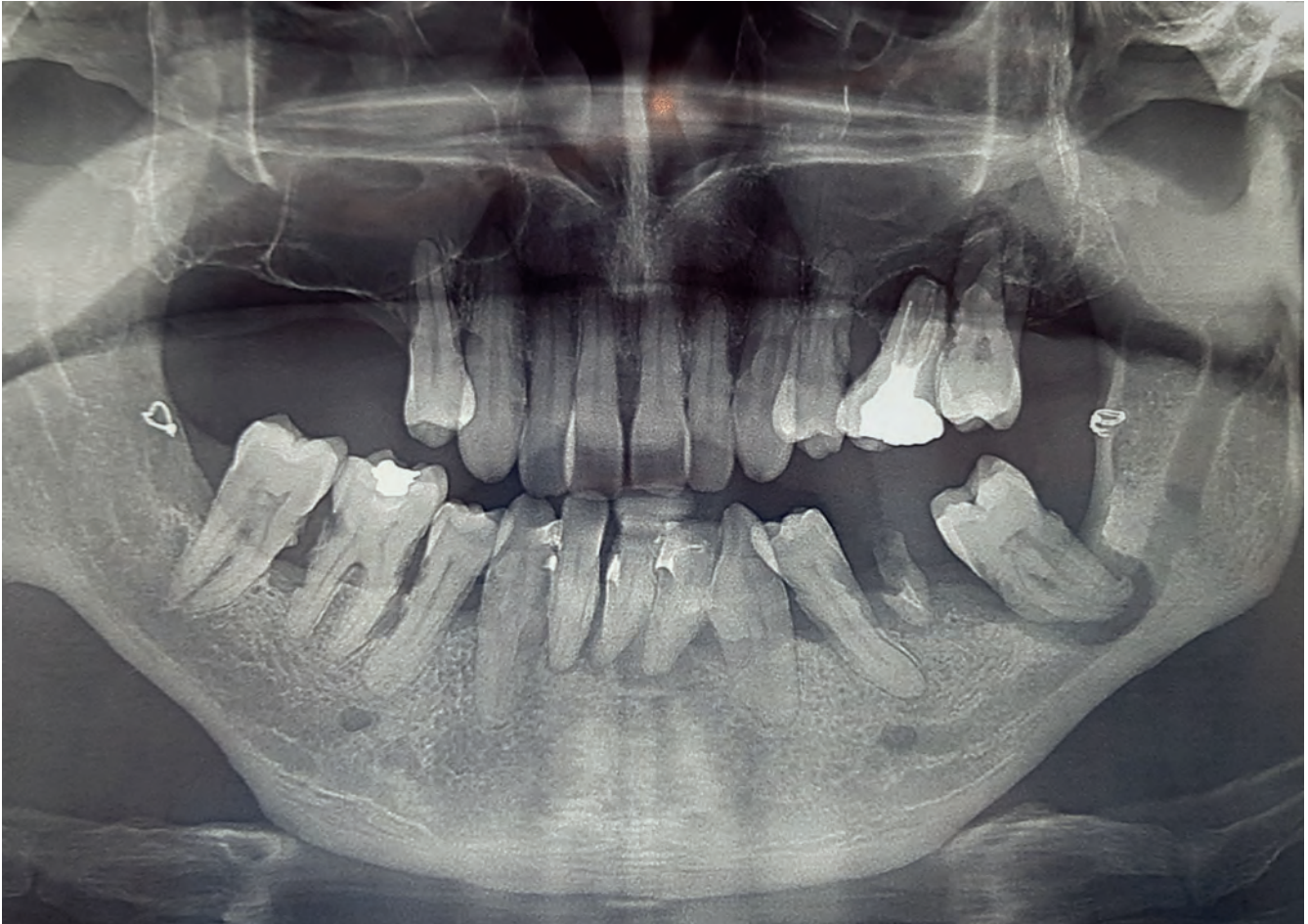

Fig. 12 Post-operative panoramic overview: Severe periodontal involvement and massive bone loss in both jaws.

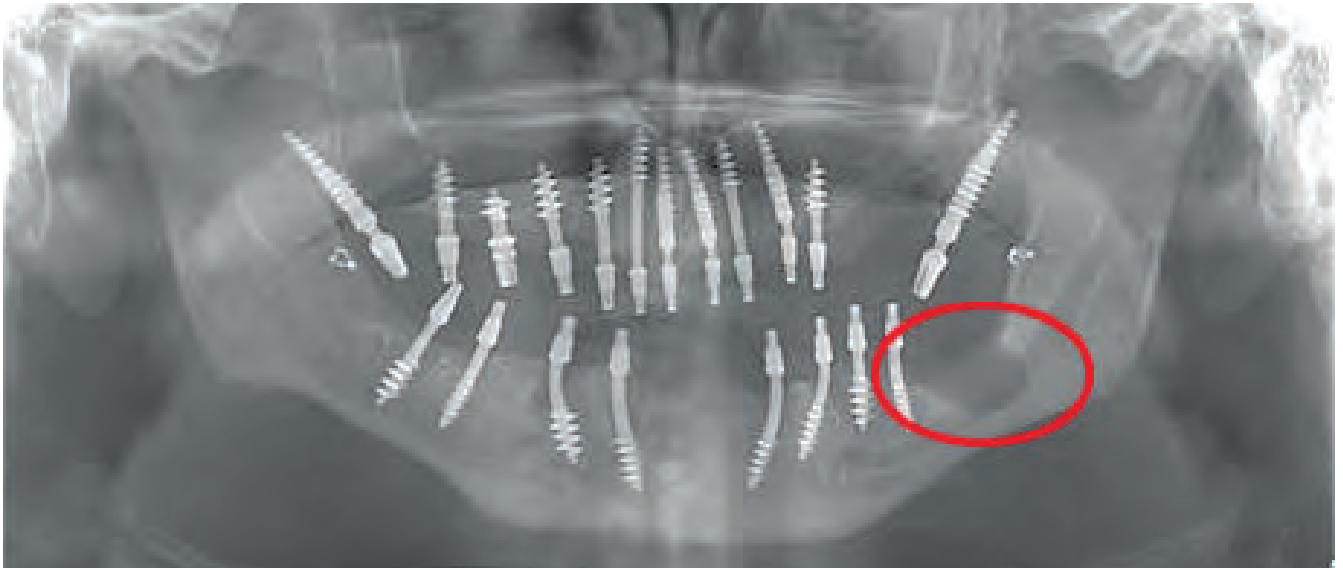


Fig. 13 Post-operative panoramic overview: The implant which had been placed in are 37 (red ring) was not very stable due to a lack of bone. It was removed after taking the impression. All implants were placed right after the removal of all teeth (see Figs. 10 and 11).

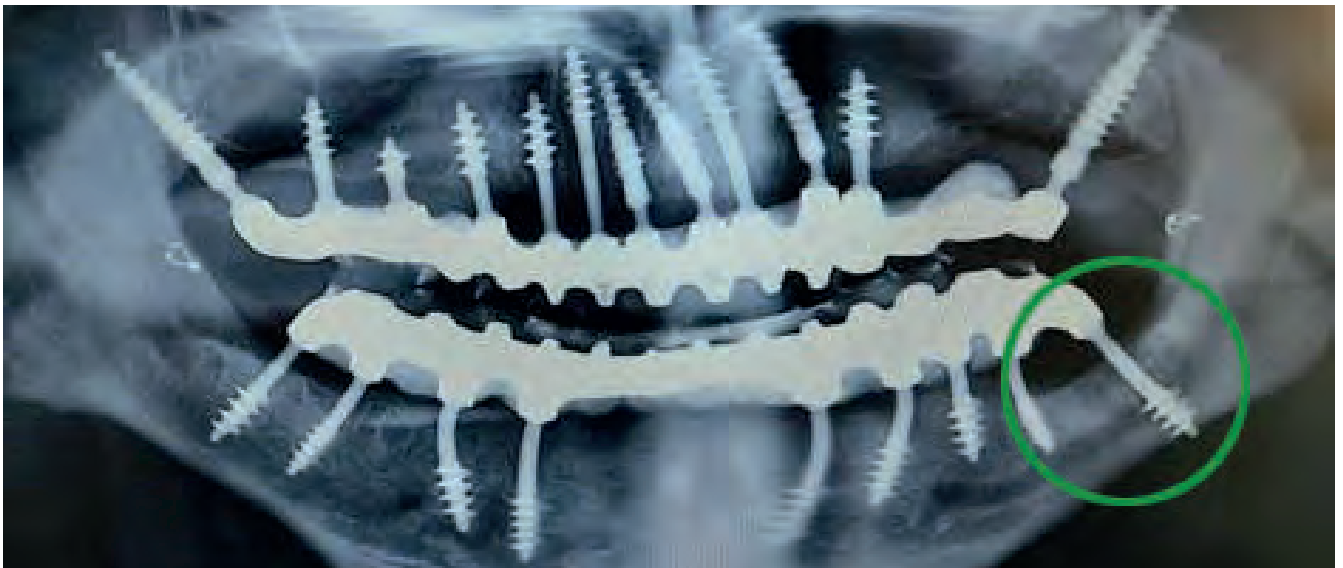

Fig. 14 Implant 37 (red ring) was placed back into the site 37 just minutes before cementing the bridge. This figure shows the view during the 8-months control. This treatment-example also shows, that "bone augmentation" is not necessary if adequate implants are chosen and the native bone in its original place is given the chance to regenerate and to build itself up.

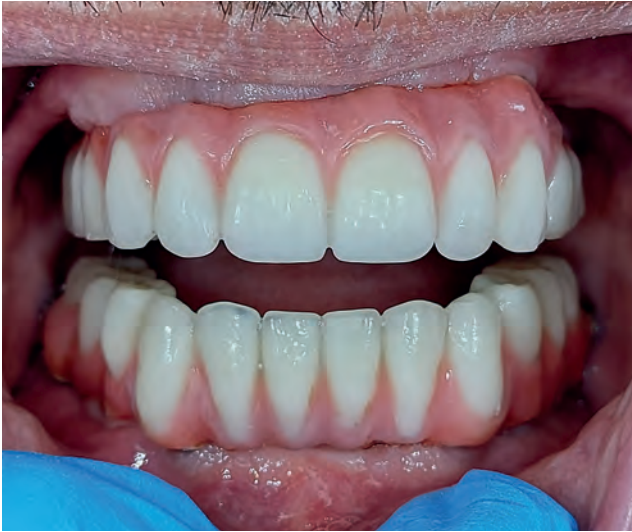

Fig. 15 8 months postoperative clinical view show fully uneventful healing. Both jaws were equipped with metal-composite-bridges.

Results of the observations

In all cases shown here we can observe the same pattern of healing around the Strategic Implant®: While the implant is anchored in the 2nd cortical, the crestal defects heal (in the sense of a re-formation of bone in extraction sockets or increase of mineralization of bone in the area of apical granulation) the same way as if no implants were placed into them. A new crestal bone-line forms in an adequate height. Likewise the total bone volume will adjust according to Wolff's law^{IV} and there are no influences nor bone loss due to "periimplantitis" expected.

Discussion

Conventional dental implants carry massive design-derived disadvantages with them, which make simple treatments as shown in the before mentioned cases absolutely impossible. The major disadvantages of conventional 2-stage implants are: their rough surface lead inevitably to bone loss along the vertical axis of the implant and often "periimplantitis" begins after 2-3 years. Their large diameters allow placement only in selected bone areas, and their 2-piece design (implant + abutment) allow mobility between the components and thereby submucosal bacterial leakage. These are three prominent reasons for "periimplantitis". Although these disadvantages are known in the profession, the conventional (2-stage) designs are still frequently used and alternatives are either unknown to or neglected by many practitioners.

The cases shown here are "hard to believe" or to understand for followers of 2-stage-concept, because such cases conflict with all prevailing assumptions. In the 2-stage world almost always bone loss happens along the vertical axis of the implants, whereas specialists trained in the Technology of the Strategic Implant® suddenly make bone grow in crestal direction along the vertical axis of the implant.

In the field of conventional dental implantology, right after implant placement, the best situation and spatial relationship between the implant and the bone is arranged. From then on the patients situation becomes only worse and worse, until the 2-stage implant is finally failing. The users

of this these 2-stage implants have accepted this situation and they accompany their patients on the road “downhill” without being able to help them.

In contrary when the Technology of the Strategic Implant® is used, the crestal bone level is allowed to arrange itself through function derived stimuli, and neither “periimplantitis” nor peri-apical infections will deteriorate the situation. The amount of jaw bone is self-adjusting and in extraction cases bone tends to grow vertically up along the polished shaft of the implant, towards the bone’s crest. As Fig. 12 and 13 demonstrate in area 37, bone will develop/grow freely upwards along the implant.

For 2-stage implantologists not only intense new learning is required but forgetting the old rules and modalities of implantology. The Technology of the Strategic Implant® is not only a little bit different for conventional implantology, it is a completely new science^v.

In 2019 the International Implant Foundation (Munich/Germany) has published a consensus on Corticobasal® Treatment Modalities, and publications by Lazarov as well as Pałka & Lazarov have made it obvious that there are two completely different “dental implantologies” available.

In the world of 2-stage-implantology, all systems are more or less the same and show only minimal differences in implant design. All those implants, regardless of the brand, have so many shortcomings and disadvantages in common, that their use should today be quite limited.

After the Technology of the Strategic Implant® has been made available to our profession, all these disadvantages are not acceptable any more. This reduces the indications for traditional 2-stage implants drastically. The answers how patients are treated with oral implants have changed.

Conclusion

The Technology of the Strategic Implant® overcomes major disadvantage of conventional implantology:

- Implants may be placed immediately after extraction of teeth and even in such situations, where peri-apical or periodontal infections are present in the masticatory system.
- Treatments are as a rule performed in an immediate functional loading protocol.
- The Technology of the Strategic Implant® utilizes only native natural bone for the implants fixation and hence bone augmentations in general and sinus-lift-procedures are unnecessary.
- Polished dental implants placed with cortical anchorage may be used for immediate-functional loading protocols.
- Patients must be fully informed about the possibilities of the Technology of the Strategic Implant® before they can give their written consent to the treatment.

This all has changed the acceptable and contemporary treatment modalities in oral implantology.

- I Pałka Ł, Lazarov A. Immediately loaded bicortical implants inserted in fresh extraction and healed sites in patients with and without a history of periodontal disease. *Ann Maxillofac Surg* 2019;9:371-8.
- II Lazarov A. Immediate functional loading: Results for the concept of the Strategic Implant®. *Ann Maxillofac Surg* 2019;9:78-88.
- III Ihde S., Ihde A., Lysenko V., Konstantinovic V. Pałka Ł. New systematic Terminology of cortical bone areals for osseo-fixated Implants in Strategic Oral Implantology. *J.J. Anatomy*, 2016, 1(2), 007
- IV Wolff J (1892): *Das Gesetz der Transformation der Knochen*. Verlag Aug. V Hirschwald, Berlin.
- V <https://www.implantfoundation.org/en/konsensuspapier-zur-sofortbelastung-von-kieferimplantatenen>